

Cervicofacial Cellulitis in the ICU (Prognostic Factors)

Kenza Damaan*, Amine Abidi, Sabah Benhamza, Mohamed Lazraq, Youssef Miloudi and Abdelhak Bensaid

Intensive care unit, 20 August Hospital 1953, Faculty of Medicine and Pharmacy, Hassan II University of Casablanca, Morocco

***Corresponding author:** Kenza Damaan, Intensive care unit, 20 August Hospital 1953, Faculty of Medicine and Pharmacy, Hassan II University of Casablanca, Morocco

Received: March 24, 2026

Published: June 15, 2026

Abstract

Background: Cervicofacial cellulitis (CFC) is a severe soft tissue infection of the head and neck with potential life-threatening complications. Early multidisciplinary management is essential to reduce morbidity and mortality.

Objective: To describe the epidemiological, clinical, and therapeutic features of CFC and identify prognostic factors associated with severe outcomes.

Methods: This retrospective descriptive study included 53 patients admitted to the intensive care unit of August 20th Hospital in Casablanca between January 2012 and May 2023. Data on demographics, risk factors, clinical presentation, imaging, microbiology, and management were analyzed.

Results: The mean incidence was 8 cases per year, with a male predominance (57%) and peak age between 45–60 years. Dental infection was the main portal of entry. Common risk factors included poorly controlled diabetes and delayed consultation (>10 days). CT imaging revealed collections in 72% and mediastinitis in 19% of cases. Difficult airway management occurred in 38% of patients, with 5.6% requiring tracheostomy. All patients underwent surgical drainage, and 28% required necrosectomy. Predominant pathogens were *Streptococcus* spp., *Staphylococcus aureus*, and *Klebsiella pneumoniae*. The mortality rate was 17%.

Conclusion: CFC is a life-threatening condition requiring early diagnosis, prompt surgical intervention, and careful airway management. Poorly controlled diabetes, delayed consultation, diffuse infection, dental origin, elevated CRP, and mediastinitis are key prognostic factors.

Keywords: Cervicofacial cellulitis; Airway management; Mediastinitis; Intensive care; Prognosis

Introduction

Cervicofacial Cellulitis (CFC) is an infection of the soft tissues of the head and neck. It is a severe condition requiring urgent, specialized multidisciplinary management to reduce morbidity and mortality.

The aim of our study was to describe the overall management of patients from their admission to the emergency department, including epidemiology, clinical presentation, complementary investigations, surgical intervention, upper airway management strategy, and to identify prognostic factors associated with severe complications of CFC.

Methods

We consecutively included 53 patients in a retrospective descriptive study, admitted to the intensive care unit of August 20th Hospital in Casablanca for cervicofacial cellulitis management, from January 2012 to May 2023.

Data were collected using a standardized data sheet from patient medical records. The main variables included age, sex, predisposing factors, portal of entry, initial symptoms, consultation delay, paraclinical findings (biological and radiological), and perioperative management, including airway management and antibiotic therapy.

Data collection complied with ethical standards regarding confidentiality and patient data protection.

Results

The prevalence was 8 cases per year. The most affected age group was between 45 and 60 years, with a male predominance (sex ratio 1.30; 57%).

The portal of entry was mainly dental. A history of tooth extraction was found in 14 patients (26%) before emergency admission. Predisposing factors included poorly controlled diabetes, poor oral hygiene, cardiovascular disease, toxic habits,

and NSAID use without antibiotic coverage.

The main presenting symptom was swelling in all patients, painful in 41% of cases, erythematous, fluctuating, and associated with fever. Limited mouth opening was also observed. Swelling was predominantly cervical: lateral cervical in 53%, median in 9.4%, but could involve other regions: jugal (24.5%), submandibular (22.6%), and retropharyngeal (7.5%).

Cervicothoracic CT scan was performed in all patients, including facial sections. A collection was found in 72% of cases and deep space infiltration in 38%. Thoracic CT revealed mediastinitis in 19% of cases.

Figure X. Cervicothoracic CT scan findings

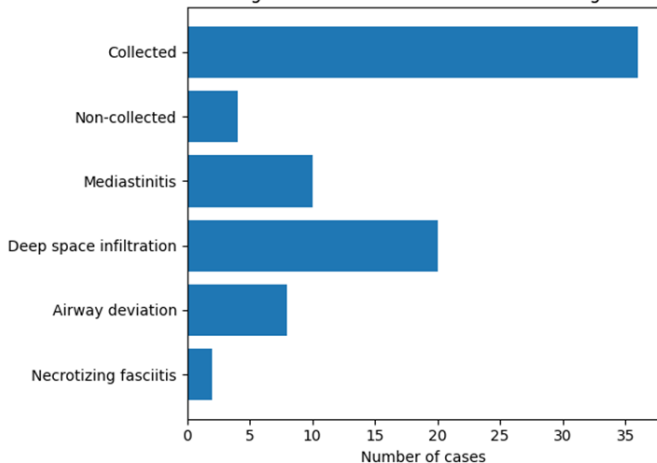


Figure 1: Cervicothoracic CT scan findings in patients with cervicofacial cellulitis.

Patients underwent surgery and were admitted to ICU for post-operative monitoring due to the risk of respiratory deterioration or hemodynamic instability. Some patients were admitted preoperatively for uncontrolled diabetes requiring stabilization before surgery.

Regarding airway management, 20 patients (38%) had difficult intubation. Among them, 3 patients (5.6%) required tracheostomy after failed intubation attempts, and 10 patients (19%) underwent fiberoptic intubation. The remaining patients were intubated using videolaryngoscopy.

All patients underwent surgical drainage under general anesthesia, and 28% required additional necrosectomy.

The most frequently isolated organisms were Streptococcus spp., Staphylococcus aureus, and Klebsiella pneumoniae. Less commonly identified pathogens included Pseudomonas aeruginosa, Enterobacter cloacae, Acinetobacter baumannii, and Lactococcus lactis.

Notably, bacteriological samples were sterile in 22.6% of cases.

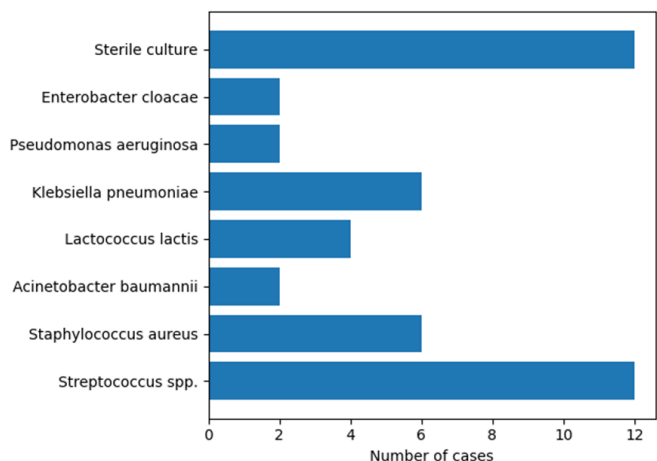


Figure 2: Distribution of bacteriological findings in cervicofacial cellulitis.

ICU management included mechanical ventilation, hemodynamic stabilization in septic shock, infection control with empirical broad-spectrum antibiotics adapted to antibiogram results, analgesia, corticosteroids in selected cases, systematic prophylactic anticoagulation (and curative in thrombophlebitis), and frequent local wound care.

Hyperbaric oxygen therapy was used in 2 patients with necrosis and refractory evolution, with favorable outcomes.

Complications included mediastinitis (3.7%), thrombophlebitis (5.6%), and septic shock (9.4%).

The mortality rate was 17%.

Prognostic factors

- Poorly controlled diabetes
- Consultation delay > 10 days
- Diffuse swelling
- Dental portal of entry
- CRP > 122 mg/L at admission
- Mediastinitis

Discussion

Cervicofacial cellulitis, also referred to as necrotizing fasciitis in the Anglo-Saxon literature, is an extensive bacterial infection involving the fascial spaces of the head and neck. Characterized by extensive tissue necrosis that may lead to severe disfigurement, it can spread to the mediastinum. These fascial planes, whose physiological role is to facilitate sliding between muscle groups, are interconnected, thereby promoting the rapid spread of initially localized infections. The locoregional portal of entry is variable, most commonly pharyngeal or dental [1–3].

In addition to local tissue damage, these infections are associated with the systemic effects of life-threatening sepsis. Cervicofacial cellulitis therefore constitutes a medico-surgical emergency with potential life-threatening implications. Prognosis depends on the number of anatomical spaces initially involved, the presence of mediastinal extension, the rapidity of clinical deterioration, the occurrence of severe sepsis, and the development of potentially serious locoregional complications [3,4].

Cervicothoracic CT scanning should be performed as early as possible [5], followed by prompt surgical intervention [6].

In contrast to conventional intubation techniques performed under general anesthesia, airway management should preferably be carried out under local anesthesia in the operating room with the patient awake. CT imaging allows assessment of the orotracheal pathway. Fiberoptic intubation is often required due to the frequent presence of pharyngolaryngeal edema with posterior displacement of the tongue base [7]. This pathological condition hinders conventional laryngeal exposure and may also compromise mask ventilation in the supine patient. Tracheostomy is not recommended as a first-line approach, as it may facilitate the spread of infection from the cervical focus to the respiratory tract.

The surgical approach must allow access to all involved anatomical compartments; therefore, precise mapping of the infection is established based on CT findings [5]. Excision of necrotic tissue is essential to control the infectious process.

Intensive care management is an integral part of the initial

treatment of cervicofacial cellulitis, alongside surgical management. Intravenous antibiotic therapy should be initiated immediately after bacteriological sampling (blood cultures and intraoperative local samples). It is initially empirical, targeting suspected pathogens—particularly streptococci (notably groups A, F, and the milleri group) and anaerobes such as *Prevotella* spp. and *Peptostreptococcus* spp. [8,9]. The regimen should be broad-spectrum, bactericidal, synergistic, and ensure adequate tissue penetration [10].

In our series, the mortality rate remained relatively high (17%) compared with the literature. This may be explained by the following prognostic factors:

- Delay in consultation: In most cases, this exceeded 10 days from symptom onset. Consequently, patients presented to the emergency department at advanced stages of infection, where edema and the size of collections posed significant challenges for airway management. Furthermore, the infection had often already spread to adjacent anatomical structures, worsening the prognosis.
- Poorly controlled diabetes: Elevated blood glucose levels and increased glycated hemoglobin were observed in 22% of patients, creating a vulnerable clinical condition and facilitating the spread of infection, sometimes extending into the thoracic region.
- Diffuse form of cervicofacial cellulitis.
- Dental portal of entry: The polymicrobial flora of the oral cavity and dental caries promote the development of swellings, predominantly in the mandibular region, often associated with collections extending to the cervical and upper thoracic regions. This can be explained anatomically by the arrangement of fascial planes and musculoskeletal structures.
- Elevated C-reactive protein (CRP).
- Mediastinitis: Among patients who developed mediastinitis, the mortality rate reached 20%, reflecting the severity and advanced stage of infection, which significantly worsens the prognosis.

In a retrospective study conducted by Romdhane et al. [11], including 159 cases and based on a multivariate analysis using a logistic regression model incorporating all variables associated with severe forms, similar prognostic factors were identi-

fied, in addition to male sex, age > 60 years, and streptococcal infection [12].

Conclusion

Cervicofacial cellulitis remains a severe condition that may be life-threatening due to its rapid progression and potential extension to the mediastinum. Management is multidisciplinary and begins upon admission to the emergency department. Close coordination between surgical and anesthesia-intensive care teams is essential for regular patient reassessment and optimization of the drainage strategy.

References

1. Huang TT, Liu TC, et al. Deep neck infection: analysis of 185 cases. *Head Neck*, 2004; 26(10): 854-860.
2. Reynolds SC, Chow AW. Life-threatening infections of the peripharyngeal and deep fascial spaces of the head and neck. *Infect Dis Clin North Am*, 2007; 21(2): 557-576.
3. Lin C, Yeh FL, et al. Necrotizing fasciitis of the head and neck: an analysis of 47 cases. *Plast Reconstr Surg*, 2001; 107(7): 1684-1693.
4. Mohammedi I, Ceruse P, et al. Cervical necrotizing fasciitis: 10 years' experience at a single institution. *Intensive Care Med*, 1999; 25(8): 829-834.
5. Becker M, Sbaren P, et al. Necrotizing fasciitis of the head and neck: role of CT in diagnosis and management. *Radiology*, 1997; 202(2): 471-476.
6. SFORL. Recommendations pour la pratique clinique - Complications locorégionales des pharyngites, 2008.
7. Reynolds SC, Chow AW. Severe soft tissue infections of the head and neck: a primer for critical care physicians. *Lung*, 2009; 187(5): 271-279.
8. Fihman V, Raskine L, et al. Cervical necrotizing fasciitis: 8 years' experience of microbiology. *Eur J Clin Microbiol Infect Dis*, 2008; 27(8): 691-695.
9. Huang TT, Tseng FY, et al. Factors affecting the bacteriology of deep neck infection: a retrospective study of 128 patients. *Acta Otolaryngol*, 2006; 126(4): 396-401.
10. Mateo J, Petipas F, Payen D. Severe cervical skin and soft tissue infections and necrotizing fasciitis. *Ann Fr Anesth Reanim*, 2006; 25(9): 975-977.
11. Hasegawa J, Hidaka H, Tateda M, Kudo T, Sagai S, Miyazaki M, et al. An analysis of clinical risk factors of deep neck infection. *Auris Nasus Larynx*. Févr 2011; 38(1): 101-107.
12. Martial DE, Kouassi ZNE, Sylvain VBT, Jules BPI, Emmanuel CG. Diffuse cervico-facial cellulitis: clinical features and risk factors of mortality. *Health Sci Dis*, 2022.