IJCMCR Open Access

International Journal of Clinical Studies & Medical Case Reports

ISSN 2692-5877
DOI: 10.46998/IJCMCR.2022.22.000538

Research Article

Insights of Stress Cardiomyopathy: From Pathophysiology to Current Treatment

Fuentes-Mendoza Juan Alan[1,6], Pimentel-Esparza Juan Andrés[2], Gómez-Monterrosas Omar[4,6], Alonso-Mercado Juan Carlos[5,6], Ricaño-Cal y Mayor Manuel[6,7] and Melano-Carranza Efrén[3,*]

[1]*Cardiology Department at PEMEX Regional Hospital Salamanca, México*
[2]*Internal Medicine PEMEX Regional Hospital Salamanca, Mexico*
[3]*Cardiac Intensive Care Unit, National Institute of Cardiology, Mexico*
[4]*Cardiology Department, Angeles Hospital, México*
[5]*Cardiac Intensive Care Unit, Medical Center ISSEMyM, México*
[6]*Posgraduate Course in Heart Failure, Zurich Heart House-Royal Brompton, United Kingdom*
[7]*Cardiac Intensive Care, American British Cowdray Hospital, Mexico*

[*]**Corresponding author:** Efren Melano Carranza, Cardiac Intensive Care Unit, National Institute of Cardiology, Medical Sur Hospital, Puente de Piedra 150, Toriello Gerra, Tlalpan, Mexico City, Mexico.

Received: September 23, 2022 **Published:** October 17, 2022

Introduction

Stress Cardiomyopathy (SC) – also known as Tako-tsubo cardiomyopathy, transient apical ballooning, and broken heart syndrome – is a disease that emerged as an essential form of acute reversible myocardial injury, produced after emotional or physical stress, and described by acute onset of chest pain and related with lectrocardiographic (ECG) changes such as ST-segment elevation, ST-segment depression, or deep T wave inversion, with cardiac biomarker (myocardial CK and troponin T or I) often marginally elevated, and transient regional Left Ventricular (LV) systolic dysfunction, which simulate an Acute Coronary Syndrome (ACS), but in the lack of obstructive coronary artery disease or plaque rupture [1-4].

Since its first description by Saton et al. and Dote et al. in 1990 [4,5], SC has increased recognition between researchers and physicians worldwide; however, it remains an underappreciated and often misdiagnosed disorder [6].

This review aims to describe SC and provide the necessary tools for diagnosis and treatment, and potential complications involved in the disease.

Epidemiology

Since the initial report by Japanese cardiologists 32 years ago, it has been gradually more recognized in clinical practice across the world [5]. SC has been reported in 1 – 3% [7] of the general population presenting with suspected ST-segment elevation myocardial infarction (STEMI) and went through urgent angiography [8].

The incidence of SC occurs in older adults and particularly in post-menopausal women (90% with mean age 67 – 70 years, and around 80% are older than 50 years) [9,10], and in the case of men, their incidence is low (range, 0 – 18%) [11]. Women older than 55 years have a fivefold more significant risk of developing SC than women younger than 55 years and a tenfold more considerable risk than men [12].

Risk Factors

There hypothesized that there exist risk factors that make some people more susceptible to this condition than others [1].

Predisposition and risk factors for SC are reviewed below:

Hormonal Factors

The significantly raised prevalence of SC in postmenopausal females suggests a hormonal influence [1] since there has been an increase of up to 5-fold increased risk in women over 55 years of age compared with younger women under 55 years of age [12].

Estrogen influences vasomotor tone by improving the coronary blood flow [13], so estrogen deprivation leads to endothelial dysfunction in postmenopausal women [14].

Psychiatric and neurologic disorders

A high association between pre-existing psychiatric and neurologic disorders has been reported in patients with SC [1,13]. In an age- and sex-matched comparison between patients with ACS and SC, psychiatric or neurologic disorders were significantly higher in SC [1].

Triggers

SC is usually triggered by an emotional or physical event, or their combination, even sometimes without any triggering event. Emotional triggers include death, severe illness, or injury involving a family member; assault and violence; receiving terrible news; financial loss; natural disasters; legal proceedings [15,16]. Nevertheless, positive emotional events can also provoke SC (birthday party, winning a jackpot, and positive job interview); this entity has been described as the happy heart syndrome [17].

The physical triggers related to SC include non-cardiac surgeries or procedures; cardiac procedures; medical conditions; medications and illegal drugs; stress tests [15,17]. Physical stimuli tend to appear more frequently compared to emotional factors. It has been observed that the patients most influenced

Copyright © All rights are reserved by Fuentes-Mendoza Juan Alan, Pimentel-Esparza Juan Andrés, Gómez-Monterrosas Omar, Alonso-Mercado Juan Carlos, Ricaño-Cal y Mayor Manuel and Melano-Carranza Efrén*

by emotional triggers are women, in contrast to patients with symptoms secondary to physical triggers, in which men predominate [9].

It is essential to mention that in some patients, there is the possibility that there is no stressful event that triggers SC since up to 30-35% have been described in cohort series [15].

Pathophysiology of SC

The pathophysiology mechanisms related to SC remain unclear, but several possible causes have been suggested to define direct or indirect myocardial damage, including sympathetic hyperexcitation, coronary vasospasm, and microvascular disorder [17]. The mechanisms described so far are listed below and represented in Figure 1.

Sympathetic activation

Acute stressors have been shown to produce brain activation, in the central and autonomic nervous systems (neocortex, hippocampus, brainstem, basal ganglia, and spinal cord) [14,18], via activation of noradrenergic neurons and sympathetic adrenomedullary circuits [14], causing increased bioavailability of cortisol, epinephrine, and norepinephrine [19].

Norepinephrine acts through β1-adrenoreceptors (β1-AR) coupled to G proteins (Gs) to increase cAMP levels and improve contractility. Epinephrine also binds β1-ARs but has a higher affinity for β2-Ars [21], which at much higher concentrations, a change in coupling occurs such that epinephrine binding to β2-ARs activates inhibitory G proteins (Gi) and has a negative inotropic effect, that explains the apical wall motion abnormalities in SC, which has been demonstrated in preclinical models [21], as did Harding et al. by showing SC changes in rats when administered high doses of bolus epinephrine [22].

Coronary vasospasm

Coronary vasospasm may be involved as another pathogenetic mechanism in SC, causing an acute, transient myocardial ischemia.

Coronary vasospasm was shown in many of the initial cases of SC in Japan on diagnostic coronary angiography, dote et al. [4] hypothesized that SC was caused by coronary vasospasm because 80% of the patients of their series had spontaneous or induced vasospasm on coronary angiography. Sato et al. [5] reported that 23% (8 of 35 patients) had epicardial coronary artery spasm and diffuse coronary vasoconstriction in 54% (19 patients). Nevertheless, subsequent studies revealed that variability of spontaneous coronary vasospasm was reported between 5 - 10% [23]. Another abnormality that might cause SC is spontaneous coronary artery dissection, an SC form triggered by an ischemic insult leading to postischemic myocardial stunning [14].

Therefore, primary vascular involvement is considered harmful, and coronary vasospasm is listed as an exclusion criterion in the diagnostic criteria [24].

Microvascular disorder

Another attractive hypothesis for SC is the abnormal coronary microvascular responses that have been revealed in invasive and non-invasive diagnostic tools [25]; however, it is transient and correlates with improvement in myocardial function [1] due to the findings found in those patients who underwent emergency coronary angiography and presented improvement in coronary flow reserve at 30 days in their follow-up [26], but this has not been universally defined [14].

Genetics Role in SC Pathophysiology

Recently, genetics has acquired significance in identifying the potential associations of genetic variations that encode molecules that raise susceptibility, protection, and severe prognosis of SC.

Familial forms. A genetic predisposition for the development of SC has been shown in siblings and mother-daughters [27].

Single nucleotide polymorphism (SNPs). The genes encoding β1, β2, and α2c adrenergic receptors (ADRB1, ADRB1, ADRA2C) have been analyzed due to their close association in the modulation of the cardiac answer to catecholamines [27].

In a cohort, Sharkey et al. [28] found no variance in the distribution occurrence of adrenoceptor ADRA2C and ADRB1 if compared with controls, in a cohort, Sharkey et al. [28] found no variance in the distribution occurrence of adrenoceptor ADRA2C and ADRB1 if compared with controls. In contrast, Spinelli et al. [29] represented the association of genetic polymorphisms in ADRB1, ADRB2, Gs-protein a subunit (GNAS), and GRK5 genes with SC, revealing a marked contrast for the polymorphism rs17098707 in the GRK5 gene, with a higher prevalence among SC patients.

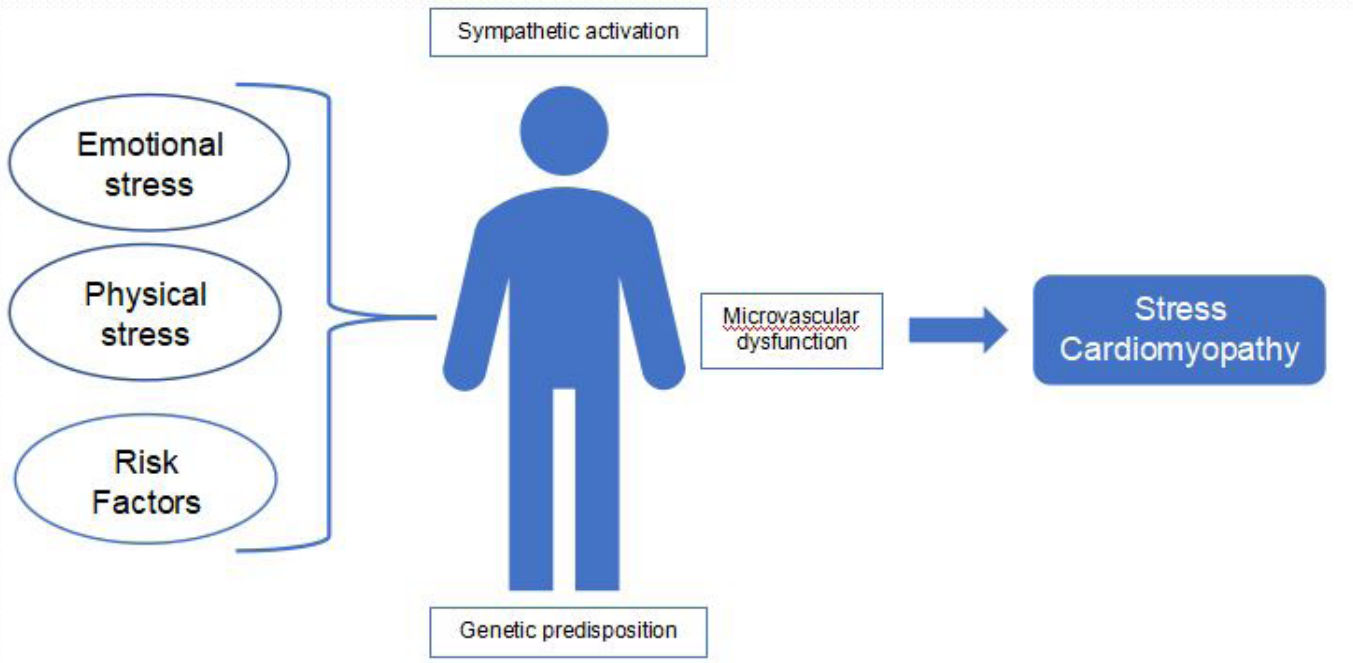

Figure 1: Pathophysiology of Stress Cardiomyopathy.

Since the polymorphism studies did not reveal significant data, some groups focused on genome-wide association study (GWAS) or Whole exome sequencing (WES) [27].

Diagnosis

SC can be challenging to diagnose as the clinical presentation is often like acute myocardial infarction (AMI). As such, SC has to be evaluated as a differential diagnosis in any patient who arrives at an emergency department with chest pain and possible ACS, mainly when accompanied by a prior intense emotional or physical stress or illness [1].

Clinical manifestations

Symptoms. The most common manifestation of SC is the acute or subacute onset of chest pain (indistinguishable from ACS) arising in approximately 60-90% of patients [9,15]. Dyspnea is another typical symptom, and less frequently orthopnea, dizziness, and syncope [15].

Physical examination. Patients with SC present respiratory (respiratory distress, crackles/rales at the bases), cardiovascular (tachycardia, hypotension, S3 gallop, jugular vein distention, and often a systolic ejection murmur), and peripheral manifestations (cold at the touch, with narrow pulse pressure, and, rarely, lower extremity edema) [30].

Electrocardiogram

The 12-lead ECG at hospital admission is central in the evaluation of all patients with chest pain, shortness of breath, and dizziness.

The most typical changes of the ECG in the SC display ischemic ST-segment and T wave changes [31], usually with T-wave inversion and significant QT interval prolongation (developing 24 – 48 hours after the start of symptoms or the precipitating stressful triggers) [32]. In patients with SC, Mitsuma et al. [33] and Kurisu et al. [34] were the first to detail the changes in the ECG, identifying an acute stage (ST-segment elevation) and subacute stage (negative T waves after resolution of ST-segment and QT interval prolongation), with ensuing gradual resolution over days to weeks [35,36]. In the SC, ST-segment elevation is centered on precordial leads V2–V5 and limb lead II and aVR [35]. Progressive T-wave inversion and QT interval prolongation are typical ECG finding in SC and closely parallel that of ST-segment elevation

Other electrocardiographic findings. Nonspecific T-wave anomalies or a normal ECG may be present in up to 35% of patients [15].

Laboratory tests

Cardiac biomarkers of myocardial necrosis (Troponin I, Troponin T, and Creatinine kinase (CK)) elevated at modest levels compared to patients with STEMI [15].

Creatine kinase–MB fraction (CKMB) is only slightly increased1. Serum cardiac natriuretic peptides (B-type natriuretic peptide (BNP) and N-terminal proBNP (NT-proBNP)) are higher at diagnosis in patients with SC [1,7] than in those with STEMI, with an enhancement within the first 24 hours from the start of symptoms and stays elevated for several days (10 days) and marginally at three months [37,38].

Echocardiography

Transthoracic echocardiography (TTE) is usually the chosen noninvasive imaging modality employed for patients with presumable SC [31] due it allows for assessing LV geometry, LV function, and anatomical variants, detecting complications, and monitoring recovery [39].

LV Wall motion and Systolic Function. Standard TTE allows the distinction of different variants that can identify based on the distribution of regional wall motion abnormalities (RWMAs) in the TTE, which contain the following and is represented in Table I:

I. Apical ballooning. The most common variants (80%) that show RWMA typically involve apical and midventricular segments, which occur with hypo-, a-, or dyskinesia, in distinction to the basal segments, which are often conserved or hyperkinetic [9,39-41]. Due to this, it was described as the Japanese word Takotsubo, "the octopus pot", in its beginnings.

II. Midventricular. The midventricular SC is distinguished by hypo-, a-, or dyskinesia of the midventricular segment [40], mild hypokinesia, or normal contraction in the apical segments and hypercontractility in the base 42.

III. This variant represents 4 - 40% of cases [41].

IV. Basal or inverted form. Two different forms define this condition, the first represented as "apical sparing" with preserved apical function and intense hypokinesis of the remaining walls, and the second as "basal or reverse" SC with hypokinesis limited to the basal segments [40].

V. Focal dysfunction.

Table I. Anatomical variants of Stress Cardiomyopathy

Apical ballooning	Midventricular	Basal or inverted	Focal dysfunction
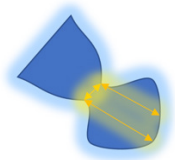	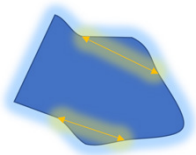	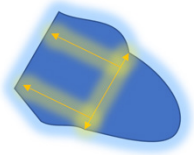	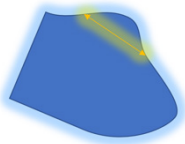

LV ejection fraction (LVEF): The assessment, in acute phases, of LVEF is also essential for the approach and diagnosis of SC; due to the results of extensive studies, LVEF and RWMA are strongly associated with significant adverse events and complications [39]. The degree of LVEF depends on the severity of myocardial impairment, the presence of comorbidities, and age [40]. Initial LVEF is usually altered on hospital admission (mean LVEF, 20 - 49%) and, in most cases, settles days-weeks after the onset of symptoms [43]. Most patients retrieve normal LVEF function during their hospital stay [16]; however, some patients may recover their functionality up to 18 days after symptoms start, according to the Pilgrim and Wyss report [44].

LV Diastolic function: Data have documented global and regional LV diastolic dysfunction during the early phase of SC, evidenced by impaired LV untwisting and increased E/e' ratio [45]; other studies have demonstrated low LV end-diastolic pressure and systemic vascular resistance [40].

Right ventricular (RV) involvement: The prevalence of RV involvement in the TIN registry was 14.5% [46]; however, its actual incidence is probably underestimated. RV dysfunction represents an additional finding that can aid in differentiating

SC and AMI [40,47].

Others

Coronary angiography (CAG): Most patients with suspected SC undergo urgent CAG to rule out ACS, though not every patient requires an invasive assessment for coronary atherothrombosis [1,30]. Patients may have angiographically normal coronary arteries or results of atherosclerosis that do not correspond with the degree of LV dysfunction or RWMA demonstrated [1]; another significant finding is spontaneous coronary artery dissection [48]. Left ventriculography is committed simultaneously with coronary angiography for a perfusion-contraction mismatch, confirms the diagnosis, and identifies the type of SC [41,49].

Cardiac magnetic resonance (CMR): Although not first line, CMR is a valuable diagnostic tool in subacute phases since it is essential in establishing the diagnosis and prognosis in patients with suspected SC whose echocardiographic images were suboptimal [41,50]. CMR can differentiate the presence of reversible injury (inflammation or ischemic edema) and irreversible myocardial damage (necrosis or fibrosis) [50]. CMR is also valuable for recognizing potential complications of SC, such as LV outflow tract obstruction (LVOTO), valve disease, pericardial effusion, and LV thrombus [50,51].

Coronary computed tomography angiography (CCTA): CCTA can be assessed in patients with limited acoustic windows by TTE and contraindication for CMR or CAG (life-threatening comorbid) [30,52]. The primary application assesses epicardial coronary artery stenosis in patients with acute chest pain with low suspicion of ACS, previous SC, and established coronary anatomy on prior recent angiography [30,31,41].

Diagnostic Criteria

The diagnosis of SC is often difficult to distinguish from an ACS due to its very similar clinical presentation; for this reason, different models have been developed over the years to diagnose SC accurately.

Since their first revision in 2004, the Mayo Clinic criteria [53] are the most widely known, but exceptions to the rule are poorly appreciated among physicians and cardiologists.

Other diagnostic models have been proposed over the years, such as the Japanese Guidelines [54], the Johns Hopkins criteria [55], the Tako-tsubo Italian Network proposal [56], and the criteria of the Heart Failure Association (HFA) Takotsubo syndrome Taskforce of the European Society of Cardiology (ESC) [31], to cite a few. Recently, the International Takotsubo Diagnostic Criteria (InterTAK Diagnostic Criteria) [32] was designed to supply clinicians with a model to assess the diagnostic probability of SC and differentiate patients from ACS.

Figure 2 illustrates the main diagnostic models of SC.

Management

Currently, there are no established international guidelines for treating SC; therefore, optimal management is based on expert consensus based on retrospective analysis.

As a general consideration, all patients with SC have to be admitted to a coronary care unit (CCU) or an intensive care unit (ICU) for the first 24 hours while achieving the diagnostic approach. To prove the diagnosis of SC, coronary angiography or echocardiography must be performed as soon as possible to exclude coronary lesions and to exhibit characteristic patterns of LV dysfunction (with or without LVOTO) [57].

Medical treatment should be individualized and established on the hemodynamic conditions of the patient. Once the diagnosis of SC is made, the patient must remain in the CCU or ICU for several days to monitor complications, which usually occur during the acute phase of SC. For patients with reduced cardiac output, physicians and cardiologists should perform regular monitoring with echocardiography [31].

Hemodynamically stable patients can be treated with Angiotensin-Converting Enzyme Inhibitors (ACEi) and beta blockers [57], and in patients with atrial or ventricular tachyarrhythmias [31]. In some cases, the administration of anxiolytic drugs is recommended; diuretics are effective for treating congestive heart failure [57].

In hemodynamically unstable patients, measures should be optimized with the aim of reduce life-threatening complications. In the case of patients with hypotension progressing to Cardiogenic Shock (CS), it is essential to determine the existence of hemodynamically significant LVOTO (LVOTO >40 mmHg and systolic blood pressure <110 mmHg) [31,58]; if LVOTO is present, inotropic medication should be discontinued immediately to avoid further obstruction because LVOTO is associated with basal hypercontractility [58]; in n these circumstances, cautious administration of beta-blockers (e.g., propranolol) can encourage the reduction of LV hypercontractility and increase diastolic filling time [57-59]; as an alternative can be indicated a selective alpha1-agonist (e.g., phenylephrine), may be effective by increasing after-load and LV cavity size [31,57].

In patients with CS without LVOTO, catecholamines should be avoided or withdrawn because it is related to the pathophysiology of SC and could aggravate the clinical status and prognosis of patients with SC [22,58]. Therapeutics options include fluid resuscitation, Intra-Aortic Balloon Counterpulsation (IABP), Extracorporeal Membrane Oxygenation (ECMO), or, if these options are not available, low-dose levosimendan infusion may be considered; however, their use in the context of SC remains controversial [60,61].

Arrhythmias frequently occur in patients with SC. New atrial fibrillation has been reported in 5–15% of cases [62]. Prolongation of QT interval was associated with ventricular arrhythmia (ventricular fibrillation or torsades de pointes) in 8.6% of patients during the acute phase of the SC [63]. In these circumstances, the administration of magnesium sulfate is suggested [57], and temporary ventricular pacing may be beneficial in these patients [64].

Long term management

Currently, there is no evidence to guide long-term management, as SC is a transient condition; complete recovery can occur within a few days or take several weeks [16]. Nevertheless, all patients should have a follow-up evaluation at 3 – 6 months [31], with new cardiac imaging studies to confirm resolution of RWMA and ECG changes.

The benefit of LV failure therapy (ACEi or angiotensin-receptor blocker (ARB), beta-blocker, and diuretics (as required)) has to last for a minimum of 3 months or until LV function is recovered [65]. Nevertheless, evidence from the International Takotsubo Registry demonstrated that the use of ACEi or ARBs was correlated with an improved survival rate at 1-year follow-up after propensity matching; in contrast, there is no evidence showing survival benefits with the use of beta blockers [9,66].

Secondary preventive measures that should be taken may include stress modulation and comorbidities, which may precipi-

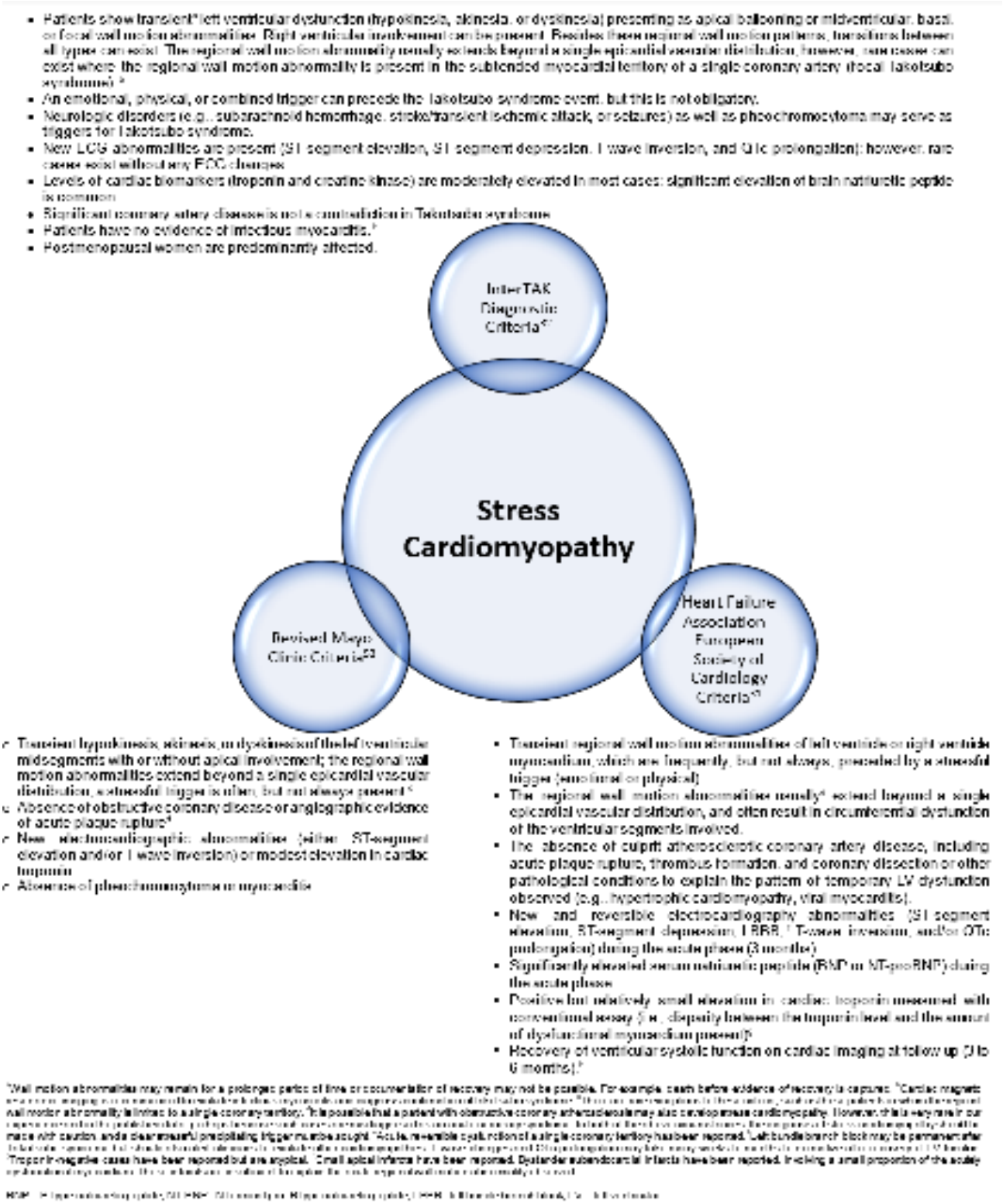

Figure 2: Diagnostic Criteria for Stress Cardiomyopathy.

tate apical ballooning and lead to SC [67].

Recurrence

Despite being a reversible pathology, SC is also recurrent, with a reported average recurrence rate from 0 – 15% [16,23], within the first few days [68] and as late as ten years [69].

Elesber et al. reported a recurrence of 2.9% per year for the first four years, decreasing to 1.3% per year after that [70]. Lau et al. [71] showed that patients treated with beta-blockers had lower mortality and recurrence, while no association was found in those treated with ACEi/ARB.

Conclusion

Stress Cardiomyopathy is a complex syndrome with a broad spectrum of hemodynamics and variable prognoses, with a clinical profile like ACS.

References

1. Assad J, Femia G, Pender P, Badie T, Rajaratnam R. Takotsubo Syndrome: A Review of Presentation, Diagnosis and Management. Clinical Medicine Insights: Cardiology, 2022; 16, 11795468211065782.
2. Luscher TF, Templin C. Is takotsubo syndrome a microvascular acute coronary syndrome? Towards of a new definition. Eur Heart J, 2016; 37: 2816–2820.

3. Merli E, Sutcliffe S, Gori M, Sutherland GG. Tako-Tsubo cardiomyopathy: new insights into the possible underlying pathophysiology. European journal of echocardiography, 2006; 7(1): 53-61.
4. Dote K, Sato H, Tateishi H, Uchida T, Ishihara M. Myocardial stunning due to simultaneous multivessel coronary spasms: a review of 5 cases. J Cardiol, 1991; 21: 203-214.
5. Sato H, Tateishi H, Dote K, et al. Tako-tsubo like left ventricular dysfunction due to multivessel coronary spasm. In: Kodama K, Haze K, Hori M, editors. Clinical Aspects of Myocardial Injury: From Ischemia to Heart Failure. Tokyo: Tokio Kagaku-hyoronsha Publ Co., 1990: 56–64.
6. Templin C, Napp LC, Ghadri JR. Takotsubo syndrome: underdiagnosed, underestimated, but understood? J Am Coll Cardiol, 2016; 67: 1937–1940.
7. Gianni M, Dentali F, Grandi AM, et al. Apical ballooning syndrome or takotsubo cardiomyopathy: a systematic review. Eur Heart J, 2006; 27: 1523-1529
8. Redfors B, Vedad R, Angerås O, et al. Mortality in takotsubo syndrome is similar to mortality in myocardial infarction - a report from the SWEDEHEART registry. Int J Cardiol, 2015; 185: 282-289.
9. Templin C, Ghadri JR, Diekmann J, et al. Clinical features and outcomes of takotsubo (stress) cardiomyopathy. N Engl J Med, 2015; 373: 929-938
10. Schneider B, Athanasiadis A, Stöllberger C, et al. Gender differences in the manifestation of tako-tsubo cardiomyopathy. Int J Cardiol. 2013; 166: 584-588.
11. Kurisu, Satoshi, et al. Presentation of Tako-tsubo cardiomyopathy in men and women. Clinical cardiology, 2010; 33: 42-45.
12. Deshmukh A, Kumar G, Pant S, Rihal C, Murugiah K, Mehta JL. Prevalence of Takotsubo cardiomyopathy in the United States. Am Heart J, 2012; 164: 66–71e1.
13. Ghadri JR, Wittstein IS, Prasad A. et al. International Expert Consensus Document on Takotsubo Syndrome (Part I): Clinical Characteristics, Diagnostic Criteria, and Pathophysiology. European Heart Journal, 2018; 39: 2032–2046.
14. Pelliccia F, Kaski JC, Crea F, et al. Pathophysiology of Takotsubo Syndrome. Circulation, 2017; 135(24): 2426–2441.
15. Summers MR, Prasad A. Takotsubo cardiomyopathy: definition and clinical profile. Heart Fail Clin, 2013; 9: 111–122.
16. Sharkey SW, Windenburg DC, Lesser JR, et al. Natural history and expansive clinical profile of stress (tako-tsubo) cardiomyopathy. J Am Coll Cardiol, 2010; 55: 333–341.
17. Ghadri JR, Sarcon A, Diekmann J, et al. InterTAK Co-investigators. Happy heart syndrome: role of positive emotional stress in takotsubo syndrome. Eur Heart J, 2016; 37: 2823–2829.
18. Suzuki H, Matsumoto Y, Kaneta T, et al. Evidence for brain activation in patients with Takotsubo cardiomyopathy. Circ J, 2014; 78: 256–258.
19. Wittstein IS, Thiemann DR, Lima JA, et al. Neurohumoral features of myocardial stunning due to sudden emotional stress. N Engl J Med, 2005; 352: 539–548.
20. Hollenberg SM. Understanding stress cardiomyopathy. Intensive Care Medicine, 2015; 42(3): 432–435. doi:10.1007/s00134-015-4018-4.
21. Lyon AR, Rees PS, Prasad S, et al. Stress (tako-tsubo) cardiomyopathy–a novel pathophysiological hypothesis to explain catecholamine-induced acute myocardial stunning. Nat Clin Pract Cardiovasc Med, 2008; 5(1): 22–29.
22. Paur H, Wright PT, Sikkel MB, et al. High levels of circulating epinephrine trigger apical cardiodepression in a β2-adrenergic receptor/Gi-dependent manner: a new model of Takotsubo cardiomyopathy. Circulation, 2012; 126(6): 697-706. doi:10.1161/circulationaha.112.111591.
23. Akashi YJ, Nef HM, Lyon AR. Epidemiology and pathophysiology of Takotsubo syndrome. Nature Reviews Cardiology, 2015; 12(7): 387–397.
24. Yoshikawa T. Takotsubo cardiomyopathy, a new concept of cardiomyopathy: Clinical features and pathophysiology. International Journal of Cardiology, 2015; 182: 297–303. doi: 10.1016/j.ijcard.2014.12.116.
25. Vitale C, Rosano GM, Kaski JC. Role of coronary microvascular dysfunction in Takotsubo cardiomyopathy. Circ J, 2016; 80: 299–305. doi: 10.1253/circj. CJ-15-1364.
26. Lyon AR, Citro R, Schneider B, et al. Pathophysiology of takotsubo syndrome: JACC state-of-the-art review. J Am Coll Cardiol, 2021; 77: 902-921.
27. Ferradini V, Vacca D, Belmonte, et al. Genetic and epigenetic factors of Takotsubo syndrome: a systematic review. International Journal of Molecular Sciences, 2021; 22(18): 9875.
28. Sharkey SW, Maron BJ, Nelson, et al. Adrenergic receptor polymorphisms in patients with stress (tako-tsubo) cardiomyopathy. J. Cardiol, 2009; 53: 53–57.
29. Spinelli L, Trimarco V, Di Marino S, et al. L41Q polymorphism of the G protein coupled receptor kinase 5 is associated with left ventricular apical ballooning syndrome. Eur. J. Heart Fail. 2010; 12: 13–16.
30. Medina de Chazal H, Del Buono MG, Keyser-Marcus L, et al. Stress cardiomyopathy diagnosis and treatment: JACC state-of-the-art review. Journal of the American College of Cardiology, 2018; 72(16): 1955-1971.
31. Lyon AR, Bossone E, Schneider B, et al. Current state of knowledge on Takotsubo syndrome: a position statement from the Taskforce on Takotsubo Syndrome of the Heart Failure Association of the European Society of Cardiology. Eur J Heart Fail 2016; 18: 8–27.
32. Ghadri JR, Cammann VL, Jurisic S, et al. A novel clinical score (InterTAK Diagnostic Score) to differentiate takotsubo syndrome from acute coronary syndrome: results from the International Takotsubo Registry. Eur J Heart Fail 2017; 19:1036–1042.
33. Mitsuma W, Kodama M, Ito M, et al. Serial electrocardiographic findings in women with Takotsubo cardiomyopathy. Am J Cardiol, 2007; 100: 106.
34. Kurisu S, Inoue I, Kawagoe T, et al. Time course of electrocardiographic changes in patients with tako-tsubo syndrome: comparison with acute myocardial infarction with minimal enzymatic release. Circ J, 2004; 68: 77.
35. Kosuge M, Kimura K. Electrocardiographic findings of takotsubo cardiomyopathy as compared with those of anterior acute myocardial infarction. J Electrocardiol, 2014; 47: 684–689.
36. Bennett J, Ferdinande B, Kayaert P, et al. Time course of electrocardiographic changes in transient left ventricular ballooning syndrome. Int J Cardiol, 2013; 169: 276–280.
37. Ahmed KA, Madhavan M, Prasad A. Brain natriuretic peptide in apical ballooning syndrome (Takotsubo/stress cardiomyopathy): comparison with acute myocardial infarction. Coron Artery Dis, 2012; 23: 259–264.
38. Nguyen TH, Neil CJ, Sverdlov AL, et al. N-terminal pro-brain natriuretic protein levels in takotsubo cardiomyopathy. Am J Cardiol, 2011; 108: 1316–1321.
39. Izumo M, Akashi A. Role of echocardiography for Takotsubo cardiomyopathy: clinical and prognostic implications. Cardiovasc Diagn Ther, 2018; 8(1): 90–100.
40. Citro R, Lyon AR, Meimoun P, et al. Standard and advanced echocardiography in takotsubo (stress) cardiomyopathy: clinical and prognostic implications. J Am Soc Echocardiogr, 2015; 28: 57-67.
41. Priya, Sarv, et al. Review of multi-modality imaging update and diagnostic work up of Takotsubo cardiomyopathy. Clinical imaging, 2021; 80: 334-347.
42. Jan MF, Tajik AJ. Modern imaging techniques in cardiomyopathies. Circulation research, 2017; 121(7): 874-891.
43. Lee JW, Kim JY. Stress-induced cardiomyopathy: the role of echocardiography. Journal of Cardiovascular Ultrasound, 2011; 19(1): 7-12.
44. Pilgrim TM, Wyss TR. Takotsubo cardiomyopathy or transient left ventricular apical ballooning syndrome: a systematic review. Int J Cardiol, 2008; 124: 283-292.
45. Meimoun P, Passos P, Benali T, et al. Assessment of left ventricular twist mechanics in tako-tsubo cardiomyopathy by two-dimensional speckle-tracking echocardiography. Eur J Echocardiogr 2011; 12: 931-9
46. Citro R, Rigo F, D'Andrea A, et al. Clinical and echocardiographic correlates of acute heart failure, cardiogenic shock and in-hospital mortality: insights from the "Tako-Tsubo Italian Network". JACC Cardiovasc Imaging 2014; 7: 119-29.
47. Hanna M, Finkelhor RS, Shaw WF, et al. Extent of right and left ventricular focal wall-motion abnormalities in differentiating transient apical ballooning syndrome from apical dysfunction as a result of coronary artery disease. J Am Soc Echocardiogr,

2007; 20: 144-150.
48. Hausvater A, Smilowitz NR, Saw J, et al. Spontaneous coronary artery dissection in patients with a provisional diagnosis of takotsubo syndrome. J Am Heart Assoc, 2019; 8(22): e013581.
49. Patel SM, Lennon RJ, Prasad A. Regional wall motion abnormality in apical ballooning syndrome (Takotsubo/stress cardiomyopathy): importance of biplane left ventriculography for differentiating from spontaneously aborted anterior myocardial infarction. Int J Cardiovasc Imaging, 2012; 28: 687–694.
50. Athanasiadis A, Schneider B, Sechtem U. Role of cardiovascular magnetic resonance in Takotsubo cardiomyopathy. Heart Fail Clin, 2013; 9: 167–176.
51. Bratis K. Cardiac magnetic resonance in takotsubo syndrome. Eur Cardiol, 2017; 12 (1): 58–62.
52. Bossone E, Lyon A, Citro R, et al. Takotsubo cardiomyopathy: an integrated multi-imaging approach. Eur Heart J Cardiovasc Imaging, 2014; 15: 366–367.
53. Bybee K, Kara T, Prasad A, Lerman A, Barsness GW, Wright RS. Systematic review: transient left ventricular apical ballooning: a syndrome that mimics ST-segment elevation myocardial infarction. Ann Intern Med, 2004; 141: 858–865.
54. Kawai S, Kitabatake A, Tomoike H. Guidelines for diagnosis of takotsubo (ampulla) cardiomyopathy. Circ J, 2007; 71: 990–992.
55. Wittstein IS. Stress cardiomyopathy: a syndrome of catecholamine-mediated myocardial stunning? Cell Mol Neurobiol, 2012; 32: 847–857.
56. Parodi G, Citro R, Bellandi B, et al. Tako-Tsubo Italian Network. Revised clinical diagnostic criteria for tako-tsubo syndrome:the Tako-tsubo Italian Network proposal. Int J Cardiol, 2014; 172: 282–328.
57. Palecek T, Kuchynka P, Linhart A. Treatment of Takotsubo cardiomyopathy. Current pharmaceutical design, 2010; 16(26): 2905-2909.
58. Kato K, Lyon AR, Ghadri JR, Templin C. Takotsubo syndrome: aetiology, presentation, and treatment. Heart, 2017; 103(18): 1461-1469.
59. Yoshioka T, Hashimoto A, Tsuchihashi K, et al. Clinical implications of midventricular obstruction and intravenous propranolol use in transient left ventricular apical ballooning (Tako-tsubo cardiomyopathy). Am Heart J 2008; 155: 526.e1-526.e7
60. Brunetti, N. D., Santoro, F., De Gennaro, L., et al. Therapy of stress (takotsubo) cardiomyopathy: present shortcomings and future perspectives. Future Cardiology, 2016;12(5), 563-572.
61. Santoro F, Ieva R, Ferraretti A et al. Safety and feasibility of levosimendan administration in takotsubo cardiomyopathy: a case series. Cardiovasc. Ther. 2013; 31, e133–e137
62. Syed FF, Asirvatham SJ, Francis J. Arrhythmia occurrence with takotsubo cardiomyopathy: a literature review. Europace, 2011; 13: 780–788.
63. Madias C, Fitzgibbons TP, Alsheikh-Ali AA et al. Acquired long QT syndrome from stress cardiomyopathy is associated with ventricular arrhythmias and torsades de pointes. Heart Rhythm, 2011; 8: 555–561.
64. Kurisu S, Kihara Y. Clinical management of takotsubo cardiomyopathy. Circ J, 2014; 78: 1559–1566.
65. de Gregorio C, Grimaldi P, Lentini C. Left ventricular thrombus formation and cardioembolic complications in patients with takotsubo-like syndrome: a systematic review. Int J Cardiol, 2008; 131: 18-24.
66. Singh K, Carson K, Usmani Z, et al. Systematic review and meta-analysis of incidence and correlates of recurrence of takotsubo cardiomyopathy. Int J Cardiol, 2014; 174: 696–701.
67. Pelliccia F, Parodi G, Greco C, et al. Comorbidities frequency in takotsubo syndrome: an international collaborative systematic review including 1109 patients. Am. J. Med, 2015; 128: 654. e11–654.e19.
68. Xu Z, Li Q, Liu R, et al. Very early recurrence of takotsubo syndrome. Ann Noninvasive Electrocardiol, 2014; 19: 93–97.
69. Cerrito M, Caragliano A, Zema D, et al. Very late recurrence of takotsubo syndrome. Ann Noninvasive Electrocardiol, 2012; 17: 58–60.
70. Elesber AA, Prasad A, Lennon RJ, et al. Four-year recurrence rate and prognosis of the apical ballooning syndrome. J. Am. Coll. Cardiol, 2007; 50: 448–452.
71. Lau C, Chiu S, Nayak, et al. Survival and risk of recurrence of takotsubo syndrome. Heart, 2021; 107(14): 1160-1166.