

## **Combining Poly-Levo-Lactic Acid and a HA-Biorevitalizer for Aesthetic Indications. A Case Report for Facial Rejuvenation**

**Alessio Redaelli\***

visiting Professor Genova University, private practice, Vascular surgery and aesthetic medicine Visconti di Modrone Medical Center, Italy

\*Corresponding author: Alessio Redaelli, Mail@docredaelli.com, via di vittoria 24, 20070 Dresano, Milan Italy

**Received:** September 04, 2023

**Published:** February 05, 2024

### **Abstract**

The author presents this case report to suggest the successful combination of Poly-Lactic Acid (PLA) dermal filler and a Hyaluronic acid Biorevitalizer (HA-Biorevitalizer) for facial rejuvenation. The aim was to assess the synergistic effects of these treatments in achieving natural-looking and long-lasting results. A comprehensive evaluation of a single patient's experience is provided, including pre-treatment assessment, treatment procedure, post-treatment follow-up, and outcomes. The results suggest that the combined approach of PLA and a HA-Biorevitalizer yielded enhanced facial volume restoration, skin texture improvement, and overall rejuvenation, reducing the risk of too strong fibrosis, visible after many sessions of PLLA diluted with distilled water alone.

**Keywords:** PLLA; HA-Biorevitalizer; Sculptra; NCTF 135 HA; Collagen; Fibrosis; Volume; Skin texture

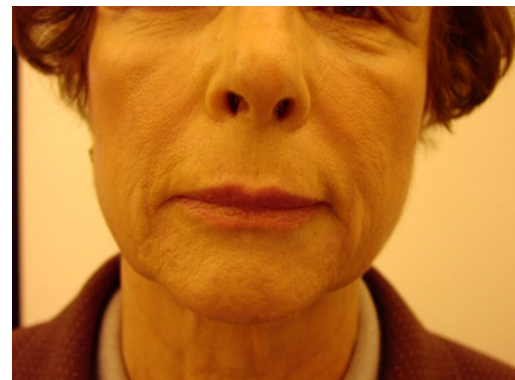
### **Introduction**

Facial aging is a multifaceted process characterized by volume loss, skin laxity, and textural changes [2]. Dermal fillers like Poly-Levo-Lactic Acid (PLLA) and biorevitalizers with Hyaluronic acid have gained popularity for their ability to address these concerns individually. PLLA stimulates collagen production, creating fibrotic collagen, very welcome in atonic patients and resulting in gradual and natural volume restoration [1,3]. It is used from many years and normally it was diluted with distilled water and lidocaine.

After many treatments the volumetrical results are really good but the possibility of a strong fibrosis of subcutaneous tissue is possible. Ha-Biorevitalizers improve skin quality through hydration and stimulation of fibroblasts [4,5] The ability of a particular HA+Biorevitalizers components to promote collagen I, elastine and cell proliferation is known from many years [5]. For this reason, the author started diluting the vial of PLLA with a HA Biorevitalizer, to get results of PLLA but reducing the risk of fibrosis. This case report explores the potential synergies of combining these treatments, diluting them in the same vial, to achieve comprehensive facial rejuvenation.

### **Case Presentation**

A 61-year-old female patient presented with concerns about facial volume loss, particularly around the cheeks, and skin texture irregularities. Comprehensive medical history assessment and facial analysis were conducted to tailor a personalized treatment plan.



*Figure 1: The lady in the picture came to my clinic for a light hollowing of the face with light volume loss, skin texture improvement and for a global facial contouring in the mid lower third of the face.*

### **Treatment Procedure**

The patient was informed about the treatment, the materials to be used and possible results. Signed an informed consent for both materials where was underlined that materials were used in "OFF Label" way, according to the author's experience.

The treatment plan involved a two-fold approach: PLLA dermal filler (Sculptra 150 mg, Galderma) diluted with 4 ml of distilled water, 2 ml lidocaine and a HA-Biorevitalizer 3 ml (NCTF 135 HA, Fillmed) for a total of 9 ml dilution. The PLLA dermal filler was strategically injected into the mid-face to restore volume gradually [3]. The Biorevitalizer, rich in hyaluronic acid and amino acids, was added to the dilution,

directly in the vial of PLLA. The dilution has been done 24 hours before the treatment and a strong “hand shake” just before the treatment was performed to well dissolve the PLLA powder. The author does not use any electrical shaker. Always a cannula 22G x 70 mm has been used. Mainly horizontal or slightly obliquous vectors were used, to avoid cumulating PLLA in a single lower point. Before the injection a gentle subcision with the cannula is done before any injection, to release dermo-subcutaneous bonds and create the right space for the hybrid filler. Then strictly linear retrograde injections have been done injecting 0,1 ml of solution for each cm of cannula. The shake of the syringe during the session, is also a very important detail to maintain a perfect and uniform dissolution of PLLA, even if this dissolution is much more stable diluting with HA-Biorevitalizer that has a gel consistency.

A perfectly well done linear retrograde injection is done injecting max 0,1 ml x cm, avoiding injection near the entry point to carefully avoid the possible formation of a hyper concentration of product that could lead to a nodule. I must underline how easy is the injection of PLLA diluted with HA-Biorevitalizer: it becomes very uniform and easy to perform without the formation of clots, frequent instead diluting with only distilled water. Over this the pain, typical of the injection of distilled water, is much reduced and patients complain much less.

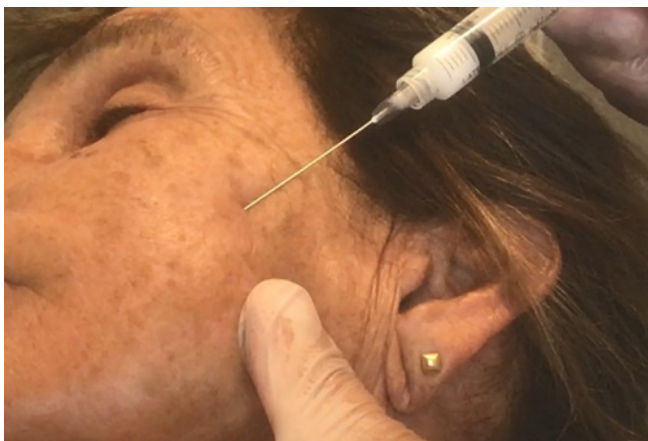

Figure 2: PLLA + HA-Biorevitalizer is injected with a 22G cannula and a fan linear retrograde technique.

If this would happen, an immediate strong massage and possibly a light local dilution injecting distilled water, should be immediately done with a following strong massage to distribute the material injected. But this happens with beginner injectors, while, with experience, is possible to avoid this side effect and get uniform in releasing the material.

A final strong massage of 20 minutes of the treated areas has been performed by the doctor and then by the patient to well distribute the filler in the subcutaneous tissue with a hydrating cream. The patient is advised on the importance of this massage to get good results and avoid nodules formation.

3 sessions have been done 45 days apart.

### Post-Treatment Follow-Up

The patient came home immediately with the task to massage the treated areas for 10 minutes twice a day for 10 days. The patient was treated for 3 sessions 45 days apart and closely monitored over this period. The patient's feedback, clinical observations, and standardized assessment scales were used to gauge treatment outcomes. No complain was registered, no bruises, no complications at all.

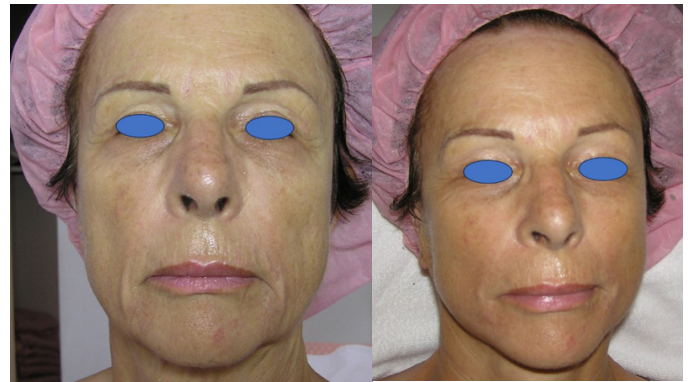

Figure 3: the patient is seen after 45 days (a) after 90 days for 3rd session and after 120 days (b) to take the picture after.

### Results

The combination of PLA dermal filler and HA-Biorevitalizer resulted in notable improvements in facial rejuvenation. After 45 days the volumization is already visible but not enough in this patient. Finally, one month after the 3rd session, a good volumetrical result was reached but especially the skin texture had a very noticeable and good result (Figure 2b). The patient appreciated a lot her results. Over the follow-up period, the patient exhibited enhanced facial volume, diminished fine lines, and improved skin texture. The gradual collagen stimulation from PLA and the hydration effects of the HA-Biorevitalizer contributed to a natural and refreshed appearance. In Figure 2b it is possible see the result after 1 month after the last 3rd session.

### Discussion

The synergistic effects observed in this case report underscore the potential benefits of combining PLLA dermal filler and HA-Biorevitalizer for facial rejuvenation. The collagen-inducing properties of PLLA complemented the skin revitalization effects of the HA-Biorevitalizer, leading to comprehensive results. With the dilution with HA Biorevitalizer the injection experience improves very much. With only distilled water the formation of little clots is frequent also using a 22G cannula and more now that a shorter dilution is suggested by the company, maybe few minutes before treatment. Instead with 1 vial HA Biorevitalizer, the injection experience improves and quit never the syringe is blocked.

Over this the immediate pain typical of distilled water injection is quit totally reduced and patients' comfort is much improved.

The staged approach allowed for gradual changes, minimizing the risk of overtreatment. Especially the light volumetrical effect and the absence, in this case total, of side effects like bruises or swelling, allowed the patient to come immediately to a totally normal life.

The wish is also that over time the typical strong fibrosis that PLLA creates, after years of treatment, will be less important. This fibrosis is our target when treating atonic patients but sometimes, in some few patients was too much. HA-Biorevitalizer allows the formation of softer collagen [5], less fibrotic, modulating in this way the full outcome to the same volumetrical effect but with softer collagen.

This result must of course be confirmed with larger numbers and in the following years confirming the author's impression with longer timing.

## Conclusion

This case report provides evidence, in this patient only, that the combination of Poly-Levo-Lactic Acid dermal filler + Ha-Biorevitalizer, is safe and did not create any complication or side effect. It was well accepted by our patient that enjoyed a lot the final results and improved injection experience by the doctor. It can lead to enhanced facial rejuvenation outcomes especially superficially.

The synergy between these treatments addresses both volume loss and skin quality, resulting in natural-looking and long-lasting results. Further studies are warranted to explore this combination on a larger scale and to determine its applicability for a broader range of patients.

## References

1. Redaelli A, et al. European expert recommendations on the use of injectable Poly-L-Lactic acid for facial rejuvenation. *J Drugs Derm*, 2014; 13(9): 1057-1066.
2. Redaelli A, et al. Facial aging: manual of aesthetic medicine. 2020 2nd revised edition.
3. Redaelli A. Poly-L-Lactic acid in aesthetic medicine: an update on indications. *Am Jour Aesth Med*, 2013; 4: 30-36.
4. Sergey Prikhnenko. Polycomponent mesotherapy formulations for the treatment of skin aging and improvement of skin quality - *Clinical, Cosmetic and Investigational Dermatol*, 2015; 8: 151-157.
5. Robin S, et al. Efficacy of a Biorevitalizing-Filler Solution on All Skin Aspects: 10 Years Approach through in Vitro Studies and Clinical Trials *Journal of Cosmetics, Dermatological Sciences and Applications*, 2021; 11(1).