IJCMCR Open Access

ISSN 2692-5877
DOI: 10.46998/IJCMCR.2023.31.000761

International Journal of
Clinical Studies & Medical Case Reports

Case Report

Applying Basic Physiology as a Rescue Strategy in Adenocarcinoma Lung Presenting with Refractory Hypoxemia Followed by Definitive Advance Intervention

Jagdeep Sharma[1], Lalita Gouri Mitra[2,*], Harsimran Singh Walia[3], Akshat Shah[4] and Falguni Hota[5]

[1]*Assistant Professor, Department of Anaesthesia, Critical care & Pain, HBCH & RC Punjab (A Unit of Tata Memorial Hospital, Mumbai). MD, DNB Anaesthesiology & Critical Care, India*

[2]*Professor, Department of Anaesthesia, Critical care & Pain, HBCH & RC Punjab (A Unit of Tata Memorial Hospital, Mumbai). MD, DNB, FICCM, India*

[3]*Assistant Professor, Department of Anaesthesia, Critical care & Pain, HBCH & RC, Punjab (A Unit of Tata Memorial Hospital, Mumbai) MD, FNB Critical Care Medicine, India*

[4]*Senior Resident, Department of Anaesthesia, Critical care & Pain, HBCH & RC, Punjab (A Unit of Tata Memorial Hospital, Mumbai). MD Anaesthesiology & Critical Care, India*

[5]*Ad-hoc Assistant Professor, Department of Interventional Radiology HBCH & RC, Punjab (A Unit of Tata Memorial Hospital, Mumbai). MD, DM Interventional Radiology, India*

***Corresponding author:** Dr. Lalita Gouri Mitra, Professor, Department of Anaesthesia, Critical care & Pain, HBCH & RC Punjab (A Unit of Tata Memorial Hospital, Mumbai), India

Received: June 13, 2023 **Published:** November 02, 2023

Abstract

We are in an evolving era of advanced infrastructural, monitoring, and interventional techniques. But basic physiological maneuvers in different aspects will always keep on contributing to tide over the crisis situations. Patients with airway obstruction due to malignancy are quite symptomatic with severe impairment of their quality of life. Various physiological maneuvers are used for improving compliance and respiratory mechanics. Postural maneuvers like prone position, lateral decubitus position have helped improve oxygen saturation levels in critically ill patients. We managed a 62-year-old male with right sided adenocarcinoma lung, presenting with respiratory difficulty due to intrathoracic extra-luminal compression of right main stem bronchus. Lateral decubitus position turned out to be a life saver for this patient. Following resuscitation and stabilization of hemodynamic parameters, this patient underwent right endobronchial stenting under general anesthesia with left sided double lumen tube. The patient got discharged in stable condition after the procedure. We emphasize the integrated and comprehensive use of basic physiological maneuvers along with advanced interventional techniques to provide a definitive solution in crisis situations.

Keywords: Lung Cancer; Acute Respiratory Failure; Dyspnea; Case Report

Introduction

Recruitment maneuvers are used for improving respiratory mechanics and in achieving oxygenation and ventilation targets. Various postural maneuvers have been used in tiding over crises. In the lateral decubitus position, the dependent alveoli stay compliant, while the non-dependent alveoli remain large and non-compliant [1]. It also helps in improving shunt fraction. Minimally invasive advanced interventional techniques have helped significantly in reducing morbidity and mortality in critical scenarios.

Case Report

A 62-year-old male with adenocarcinoma right lung presented with severe breathing difficulty and diaphoresis. He was a known hypertensive, chronic smoker for 15 years with severe restriction (pulmonary function tests- forced vital capacity (FVC-30.8 %) & forced expiratory volume (FEV1-34.2 %). Contrast-enhanced computed tomography scan of the thorax showed a large mass encasing the right main bronchus and all three lobar bronchi, causing complete luminal obstruction with the collapse of the right lung. He was agitated with a respiratory rate of 40/min. Hemodynamic parameters with heart rate 144/min, blood pressure 144/96 mmHg, and oxygen saturation (spO2) was 50% on room air, The patient was put on a high-flow nasal cannula with saturation not improving, and signs of peripheral cyanosis being evident.

The patient was intubated and put on mechanical ventilation. Even on a 100% fraction of inspired oxygen (Fi02), the spO2 remained at 70-75%. The right side of the chest was not ex-

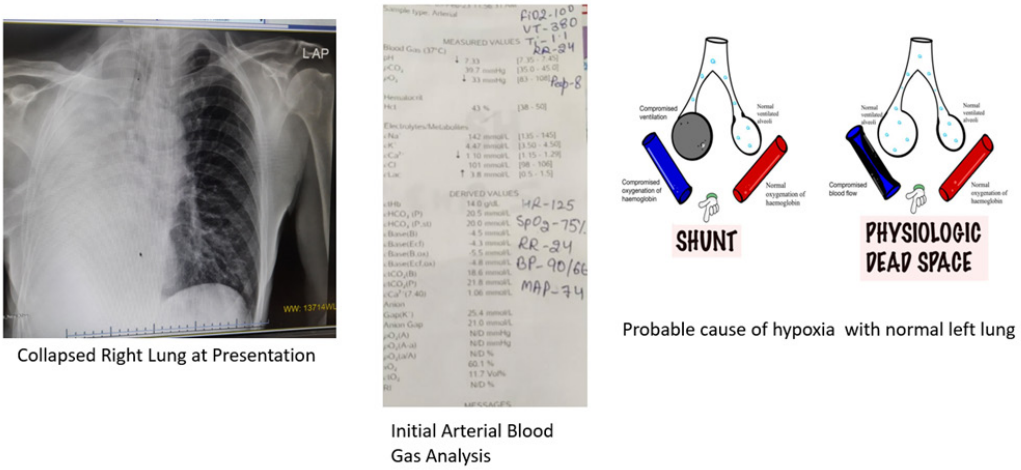

Figure 1: Chest X-Ray showing collapsed right lung at presentation, ABG after intubation and Probable cause of hypoxia with normal left lung.

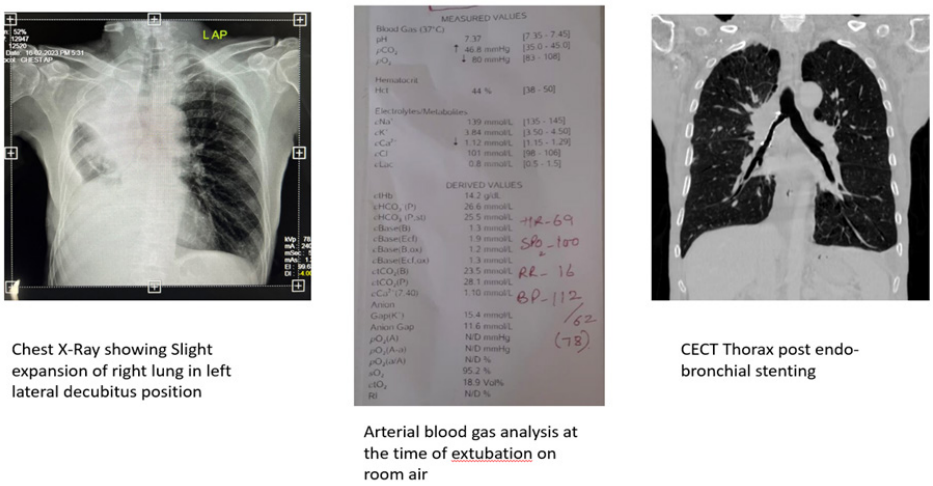

Figure 2: Chest X-Ray showing slight expansion of right lung in left lateral decubitus position, Arterial blood Gas Analysis on extubation in lateral decubitus position and CECT Thorax post endobronchial stenting.

panding, and there were no breath sounds on auscultation. A chest x-ray also showed a completely right lung collapse. Arterial blood gas analysis showed severe hypoxia with partial pressure of oxygen 33mmHg and saturation of oxygen 60% **(Figure 1)**.

The treatment started with antibiotics, bronchodilators, along with advanced hemodynamic monitoring. As refractory hypoxemia persisted, we applied basic physiology, viz. a positional maneuver and patient made to left lateral decubitus position. Within hours the oxygen saturation levels improved to 95-96%. The FiO2 was reduced to 40% as the blood gas values improved. Repeat chest X-ray also showed slight expansion of the right lung in the lateral decubitus position.

After a multi-disciplinary team discussion, a high dose of external beam radiation therapy was given, and the patient was successfully weaned and extubated in the left lateral decubitus position on day 3. The patient stayed stable in high dependency unit. On day 5 patient underwent right endobronchial stenting under general anesthesia with one-lung ventilation (lung isolation done with 37 Fr left-sided double-lumen tube. Following stenting in the interventional radiology suite, the CECT thorax showed full expansion of the right lung **(Figure 2)**. He was extubated after overnight ventilation and shifted to the ward the following morning.

Discussion

Patients with malignancy-induced airway obstruction are symptomatic with severe impairment of their quality of life. Airway obstruction can be endoluminal, extra-luminal, or a combination of both [2]. Postural maneuver, like lateral decubitus position, helps improve oxygenation by reopening and keeping open non-aerated parts of the lung. During lateral positioning, the differential effect of gravity on each lung can modify regional transpulmonary pressures that may help re-expand collapsed segments [3,4]. Minimally invasive interventions in different aspects have a significant impact on safe patient outcomes. They help significantly reduce the morbidity and mortality of critically ill patients.

In an era of advanced treatment shifts, revisiting and applying basic physiology can help bridge a crisis. Our case is an excellent integration of basic physiological maneuver along with advanced interventional radiology technique to provide a definitive solution for complex medical issues.

Conflict of Interest: None
Funding: None

References

1. Lohser J, Ishikawa S. Physiology of the Lateral Decubitus Position, Open Chest and One-Lung Ventilation, 2011; 78.
2. Oberg C, Folch E, Santacruz J. Management of malignant airway obstruction. AME Medical Journal, 2018; 3.
3. Roldán R, Rodriguez S, Barriga F, et al. Sequential lateral positioning as a new lung recruitment maneuver: an exploratory study in early mechanically ventilated Covid-19 ARDS patients. Ann. Intensive Care, 2022; 12: 13.
4. Constantin JM, Godet T, Jabaudon M, Bazin JE, Futier E. Recruitment maneuvers in acute respiratory distress syndrome. Ann Transl Med, 2017; 5(14): 290.