

**Case Report**

**Chronic Suppurative Osteomyelitis of Maxilla Mimicking Actinomycotic**

**Osteomyelitis in Post Covid Patient: A Rare Case Report**

Sanjay Kumar Singh, Praveen Kumar Pandey, Indrajeet Singh, Rachna Saini, Sudhanshu Agrawal\*

*Department of Oral & Maxillofacial Surgery, Chandra Dental College & Hospital, India*

\*Corresponding author: Sudhanshu Agrawal, Department of Oral & Maxillofacial Surgery, Chandra Dental College & Hospital, Barabanki, India

Received: October 18, 2021

Published: November 12, 2021

**Abstract**

Osteomyelitis is a disease which is heterogeneous in its pathophysiology, clinical presentation and management. It is considered to be one of the most difficult to treat infectious diseases. Progressive bony destruction and the formation of sequestra are hallmarks of osteomyelitis. We hereby report a rare case of left maxillary osteomyelitis, which had actinomycotic osteomyelitis like presentation but was histopathologically diagnosed as a severe form of chronic suppurative osteomyelitis.

**Keywords:** Actinomycotic osteomyelitis, chronic suppurative osteomyelitis, osteomyelitis

**Introduction**

Osteomyelitis is an inflammatory condition of bone, involving the medullary cavity and the adjacent cortex. It occurs more frequently in the mandible than in the maxilla; [1] although most of the cases of osteomyelitis of the jaws are of odontogenic origin, other sources of infection are also reported [2]. The condition was originally described by Rees in 1947 [3]. It is an inflammatory reaction of bone to infection which originates from a tooth, fracture site, soft tissue wound or surgical site. The dental infection may be from a root canal, a periodontal ligament or an extraction site. Suppurative osteomyelitis can involve all three components of bone: periosteum, cortex and marrow. Osteomyelitis of the maxilla is much less frequent than that of the mandible because the maxillary blood supply is more extensive. Thin cortical plate and a relatively rare paucity of medullary tissue in the maxilla preclude confinement of infection within bone and permit the dissipation of edema and pus into the soft tissue and paranasal sinuses [4]. The maxilla rarely undergoes necrosis, due to its rich vascularity. Maxillary necrosis can occur due to bacterial infections such as osteomyelitis, viral infections such as herpes zoster or fungal infections such as mucormycosis, aspergillosis, etc. [5]. In established suppurative osteomyelitis, symptoms include deep pain, malaise, fever and anorexia. Within 10-14 days after onset, teeth in the involved area begin to loosen and become sensitive to percussion. Pus exudes around the gingival sulcus or through mucosal and cutaneous fistulae. Firm cellulitis of the cheek, enlargement of the dimensions of the bone from increased periosteal activity, abscess formation with localized warmth, erythema and tenderness to palpation may be noted. Osteomyelitis of the jaws usually requires both medical and surgical treatment.

**Case Report**

We hereby report a rare case of osteomyelitis in an otherwise healthy patient who reported to OPD of Oral and Maxillofacial Surgery Department of Chandra Dental College and Hospital, Safedabad, Barabanki, U.P. with complaints of multiple pus discharging sinuses (Figure 1) as is usually seen in actinomycotic conditions, associated with pain in the upper jaw. On examination, there was generalized mobility of all the maxillary teeth, associated with bone exposure (sequestrum) in the left maxillary molar region on the buccal aspect.

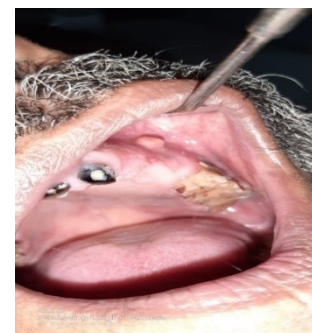


Figure 1: Multiple pus discharging sinuses.

Orthopantomogram (OPG) was advised, which showed (Figure 2) areas of bone loss in the maxilla around the teeth from first molar of one side to the first molar of the other side.

The provisional diagnosis was osteomyelitis of the maxilla with spontaneous sequestration. An incisional biopsy and a culture and sensitivity test were performed under local anesthesia, after getting the blood examination done and under antibiotic coverage (amox + clav and metrogy) (Figure 3).

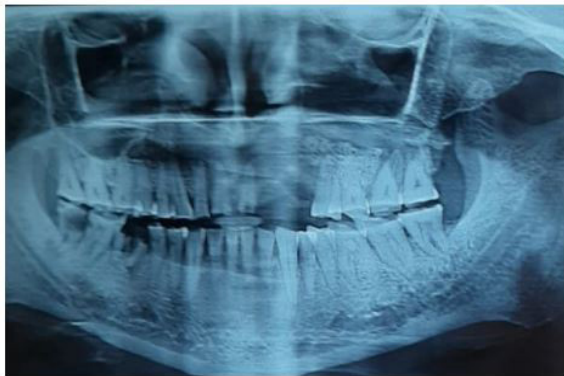


Figure 2: Preoperative OPG.

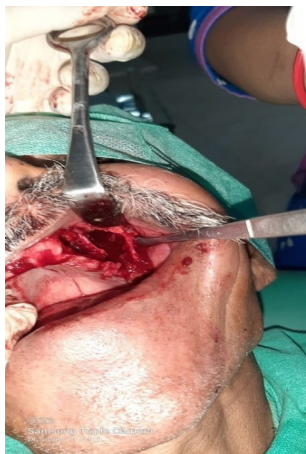

Figure 3: Intraoperative – Flap elevation and exposure of the lesion.

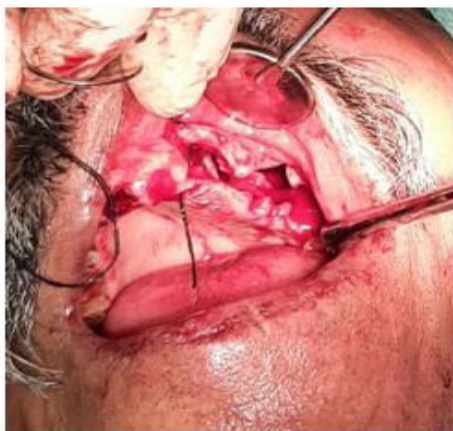

Figure 4: Intraoperative – lesion removal.

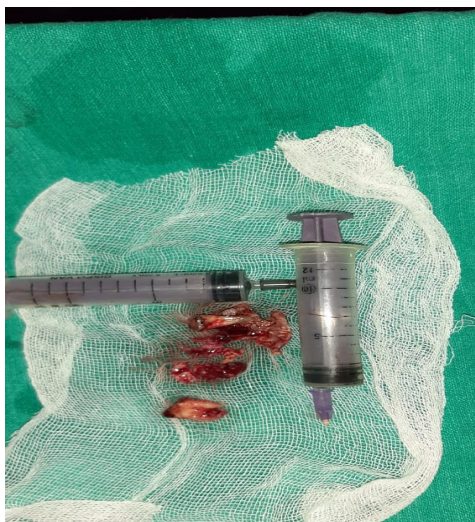

Figure 5: Pathology with root stumps.

The exposed sequestrum was removed along with the decayed root stumps and histopathologic diagnosis was chronic suppurative osteomyelitis. (Figure 4,5).

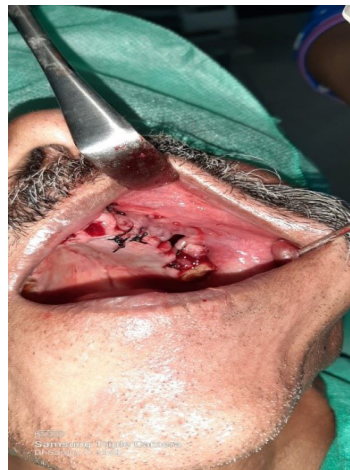

Figure 6: Closure with suction drain.

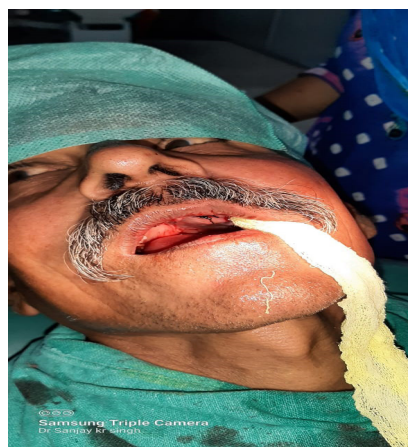

Figure 7: Intraoperative – Iodoform dressing pack.

Since it was a suppurative lesion and was associated with sinus formation, the patient was kept on antibiotic coverage for 2 weeks, which drastically improved the condition (Figure 6). Dressing is repeated regularly after three days and in history of present illness. Only sinus was present with mobile tooth. During surgery extraction of tooth done with alveolectomy and curettage done. Sequestrectomy and curettage was performed along with total extraction of the maxillary left side teeth and maxillary alveolectomy and iodoform dressing pack placed (Figure 7).

The postoperative period was uneventful. Patient was kept under antibiotic coverage. Regular irrigation with betadine was being performed on a daily basis and drain was removed on 4th postoperative day and suture was removed on 8th postoperative day. The excision biopsy report confirmed the lesion to be chronic suppurative osteomyelitis of maxilla, which is obviously a rare condition. The healing was uneventful [Figure 8]. The patient is under regular follow-up.

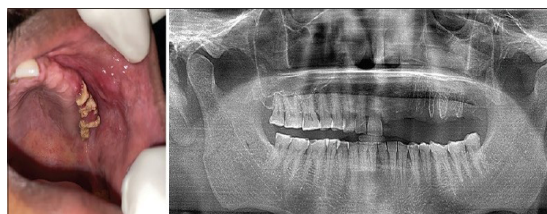

Figure 8: OPG after 6 months.



## Discussion

Osteomyelitis is a disease which is heterogeneous in its pathophysiology, clinical presentation and management. It is considered to be one of the most difficult-to-treat infectious diseases. Progressive bony destruction and the formation of sequestra are hallmarks of osteomyelitis. Osteomyelitis can result from hematogenous seeding, contiguous spread of infection, or direct inoculation of microorganism(s) into intact bone [6].

Diminished host defenses, both local and systemic, can contribute significantly to the emergence and clinical course of the disease. Osteomyelitis has been associated with multiple systemic disease including diabetes, autoimmune status, malignancies, malnutrition and acquired immunodeficiency syndrome [7]. The medications linked to osteomyelitis are steroids, chemotherapeutic agents and bisphosphonates [7,8], whereas in our case the patient was absolutely free of the above-mentioned conditions and the source of infection seemed to be rather of periodontal origin.

Infection of the maxilla can cause serious complications for the patient such as infection of cranial cavity and brain. Thus, it is essential that any maxillary osteomyelitis be treated aggressively by the surgeon to avoid subsequent dreaded consequences.

The clinical presentation of multiple pus discharging sinuses were typical of actinomycotic infection, which was ruled only out after culture of the pus sample. The actinomycotic infection forms external sinuses that discharge distinctive sulfur granules and spreads unimpeded by anatomical barriers [4]. Nearly every structure and space of the head and neck may be the initial site of involvement [9].

Despite important medical and surgical advances in the management of patients with osteomyelitis, this disease remains extremely difficult to treat. The relapse rate can be as high as 20%. The usual goal of therapy is the eradication of the infection and restoration of function. Treatment of established osteomyelitis requires aggressive surgical debridement and prolonged antimicrobial therapy in the majority of cases [6]. Cohen et al., [10], successfully used the combination of antibiotic therapy and surgery when treating a patient with chronic jaw osteomyelitis the authors administered vancomycin and surgical debridement was performed until the underlying bone

started bleeding. Antibiotic therapy was administered for an additional month and the lesion was cured. Chronic osteomyelitis is usually treated by the combination of antibiotic therapy and surgical debridement of the lesion [11].

## Conclusion

Adult osteomyelitis remains difficult to treat, with considerable morbidity and costs to the health care system. Osteomyelitis is now such a rare entity that when presented, the maxillofacial surgeon should consider the possibility underlying pathology and investigate appropriately. The term "cure" is not used for osteomyelitis because the infection may recur years after apparent successful treatment of the disease, if the patient suffers new trauma to the involved area, or the host response to the infection is suppressed. The goal of treatment is to arrest osteomyelitis, rather than achieve cure and so the patient is being followed up till date with no signs of recurrence.

## References

1. Moose SM, Marshall KJ. Textbook of oral and maxillofacial surgery. In: Kruger GO, editor. St. Louis: CV Mosby, 1979; p. 204-207.
2. Sivapathasundharam B. Shafer's Textbook of oral pathology, 6th ed. Noida: Elsevier, 2009; p. 492.
3. Mccash CR, Rowe NL. Acute osteomyelitis of maxilla in infancy. *J Bone Joint Surg Br* 1953; 35: 22-32.
4. Topazian RG. Oral and maxillofacial infections. 4th ed. Philadelphia, Pennsylvania: W. B. Saunders and Company, 2002.
5. Auluck A. Maxillary necrosis by mucormycosis: A case report and literature review. *Med Oral Patol Oral Cir Bucal*, 2007; 12: E360-E364.
6. Sia IG, Berbari EF. Infection and musculoskeletal conditions: Osteomyelitis. *Best Pract Res Clin Rheumatol* 2006; 20: 1065-1081.
7. Marx RE. Chronic osteomyelitis of the jaws. *Oral Maxillofac Clin North Am* 1991; 3: 367-381.
8. Marx RE. Pamidronate and zoledronate induced avascular bone necrosis. *J Oral Maxillofac Surg* 2003; 61: 1115-1118
9. Lerner PI. The lumpy jaw. Cervicofacial actinomycosis. *Infect Dis Clin North Am* 1988; 2: 203-220.
10. Cohen MA, Embil JM, Canosa T. Osteomyelitis of the maxilla caused by methicillin-resistant *Staphylococcus aureus*. *J Oral Maxillofac Surg* 2003; 61: 387-390.
11. Harvey BR, Ephros H, Defalco RJ. Tetracycline bone labeling in surgical management of chronic osteomyelitis: A case report. *J Oral Maxillofac Surg* 2004; 62: 752-754.