IJCMCR Open Access

International Journal of Clinical Studies & Medical Case Reports

ISSN 2692-5877
DOI: 10.46998/IJCMCR.2020.03.000069

Case Report

COVID 19: Unveiling a Novel Fomite of Post Injection Endophthalmitis

Megbelayin EO[1]* and Babalola YO[2]

[1]*Department of Ophthalmology, University of Uyo, Nigeria*

[2]*Department of Ophthalmology, University of Ibadan, Nigeria*

***Corresponding author:** Megbelayin Emmanuel Olu, Department of Ophthalmology, University of Uyo, Nigeria. E-mail: favouredolu@yahoo.com

Received: July 24, 2020 Published: August 20, 2020

Abstract

A 54-year old man received intravitreal bevacizumab for macular edema due to macular branch retinal vein occlusion. Patient had a repeatedly used face mask on during and after injection 2 days after injection, he reported with features of endophthalmitis. Vision remained Hand Movement for a week despite 4 doses of intravitreal Vancomycin and Ceftazidime. This necessitated a core vitrectomy.

Key words: Endophthalmitis; Intravitreal; Bevacizumab; Vitrectomy

History

A 54-year old man presented with 2 weeks history of progressive blurring of vision in the right eye. There was no associated pain tearing, redness, discharge, photophobia, haloes around light or antecedent trauma. He has been on antiglaucoma medications for 2 years with a well-controlled intraocular pressure. The last pair of glasses was obtained 2 years back and no previous ocular surgeries. He is hypertensive but not diabetic.

On Examination

Aided visual acuity was 6/60 and 6/9 and Intraocular pressures were 12 and 14mmHg respectively. Anterior segments were essentially within normal limits in both eyes. Except for a cup disc ratio (CDR) of 0.8, the posterior segment of left eye was within normal limits. On the other hand, the left eye has a CDR of 0.7, multiple intraretinal haemorrhages confined to the arcade and macular edema which was confirmed by Optical Coherence Tomography.

Patient subsequently had intravitreal bevacizumab (Avastin; Genentech) 1.25mg/0.05ml in the right eye. Injection followed aseptic procedures routinely adhered to by our facility. This included 10% providone iodine for periocular skin preparation, generous 5% providone iodine application to ocular surface, meticulous draping that excluded eyelashes from ocular surface and injection site, creating a conjunctival needle site injection mismatch and immediate cotton bud application on removing the 30G needle that was used. Topical ciprofloxacin 0.3% four times daily for 5 days was advised. Two days post injection he reported with significant diminution in vision with an unaided visual acuity of Hand Movement, redness and tearing. Slit-lamp examination revealed hairline hypopyon with absent red reflex on indirect ophthalmoscopy with B-scan showing multiple clump and dot moderate reflective echoes in the vitreous (Figure 1).

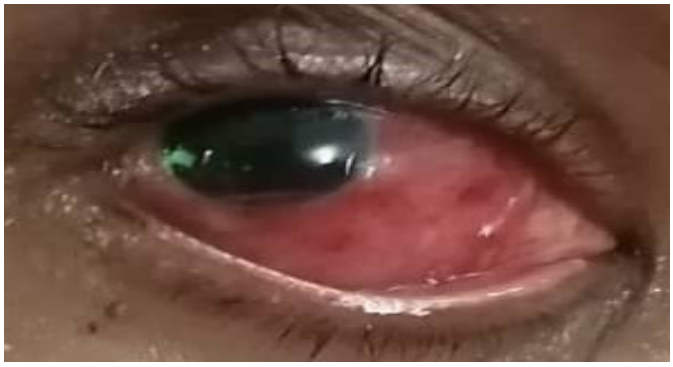

Figure 1: Hyperemic eye with hypopyon seen after 2 days of intravitreal injection.

Intravitreal Vancomycin (1.0 mg/0.1 mL) and ceftazidime (2.25 mg/0.1 mL) were administered, with subconjunctival gentamycin, tab ciprofloxacin 500mg twice daily, intravenous ceftriaxone 1 gram daily for 2 days, half-hourly 0.3% moxifloxacin and tobramycin ointment nocte. Core vitrectomy was done a week after when vision did not improve beyond Hand Movement because of dense vitreous opacities.

Discussion

COVID-19 (Corona Virus Disease, reported in Wuhan, China in 2019) was declared a pandemic by the World Health Organization having unleased significant morbidity and mortality globally [1-3]. The avidity of its spread demands that face masks, social distancing, hand washing and sanitizing be practiced by everyone. These preventive measures have proven to be effective in curtailing the spread of the deadly Corona virus. Endophthalmitis is a devastating complication of intravitreal injections [4-8]. Avastin is an off-label anti-vascular endothelial growth factor often used as aliquots or as multiple dosing from its vial [9-11]. Apart from repeated puncturing of

Avastin vial, other possible sources of infection following intravitreal injection of anti-vascular endothelial growth factors (anti-VEGFs) are compromised cold chain system, technique of periocular skin preparation, whether providone iodine is used or not. Operating theatre microbial status, patient's post-injection ocular practices and injection technique may also be linked with endophthalmitis.

The advent of COVID-19 may have introduced a paradigm of a new hitherto unidentified source of endophthalmitis. Before now, patients do not wear face masks routinely for ophthalmic procedures. It is now a prudent decision to ensure ophthalmic patients wear face mask at outpatient clinics and during surgery. The demands for face masks have led to astronomical increase making daily replacement infeasible. Face masks which ought to be used once and disposed is often reused without being sterilized making it a fomite for infection transmission especially to parts of the body it is closely associated like the eye. This index patient had a face mask that had been repeatedly used for a week prior to injection.

The authors believe that face mask was the most likely culprit of patient's infection. The microscopy/culture result of Avastin sample yielded a negative result. In addition, there was no breach in all injection procedures or theatre environment which have been used for previous patients in the past three years who did not develop infection. The index patient was the first to ever wear a face mask during and immediately after intravitreal injection. Unfortunately, there was no way to culture the face mask, however, vitreous tap yield gram positive Streptococci Spp which may have originated from the face mask. Face mask in the authors' opinions have two potential ways of introducing ocular infection. It could be by direct inoculation as a fomite in which a contaminated finger from face mask is used to rub on the eye. Secondly, face mask is not leak proof, hence, contaminated breaths from nostrils or droplets from the mouth while talking are channeled into the eyes. Areas around the nose leave some spaces whenever facemasks are on giving room to escape of hot contaminated air from oro-nasal cavity. Chen et al noted that Streptococci Viridans which originates from the oral cavity has three times chance to cause post-injection endophthalmitis [8].

This article aims to raise an alarm that COVID-19 prevention with face mask may have introduced a silent source of endophthalmitis. To obviate this potential source of infection, it is recommended that a sterile face mask or at least a brand new face mask be used by the patient during intravitreal injection. It is also suggested that a sterile face mask or a daily brand new face mask be used for at least 2 days after and perhaps topical antibiotic frequency be increased to 2-hourly instead of the 4 times as routinely practiced by the authors. Although some studies have refuted the benefits of post-injection topical antibiotics [12,13]. A strict no-talking policy during intravitreal injection could reduce incidence of infection and add as extra safety measure [14].

References

1. Zhu N, Zhang D, Wang W, Li X, Yang B, Song J, et al. A Novel Coronavirus from Patients with Pneumonia in China, 2019. N Engl J Med. 2020;38:727-33.
2. Turakhia S, Saoji Y, Goyal A, Chande P, Hussaindeen JR, Konda N, et al. COVID-19 guidelines for optometry and optical services postlockdown. Indian J Ophthalmol. 2020;68:1533-9.
3. Agarwal R, Sharma N. Commentary: COVID-19 pandemic and national lockdown: The cascading effect. Indian J Ophthalmol. 2020;68:1545.
4. Dave VP, Pappuru RR, Khader MA, Basu S, Tyagi M, Pathengay A. Endophthalmitis with opaque cornea managed with primary endoscopic vitrectomy and secondary keratoplasty: Presentations and outcomes. Indian J Ophthalmol. 2020;68:1587-92.
5. Dave VP, Pathengay A, Budhiraja I, Sharma S, Pappuru RR, Tyagi M, et al. Clinical presentation, microbiologic profile and factors predicting outcomes in Bacillus endophthalmitis. Retina. 2018;38:1019-23.
6. Kernt M Kampik A. Endophthalmitis: Pathogenesis, clinical presentation, management, and perspectives. Clin Ophthalmol. 2010;4:121-135.
7. Shah PC, Garg SJ, Vander JF, Brown GC, Kaiser RS, Haller JA, et al. Outcomes and Risk Factors Associated with Endophthalmitis after Intravitreal Injection of Anti-Vascular Endothelial Growth Factor Agents. Ophthalmology. 2011;118(10):2028-2034.
8. Chen E, Lin MY, Cox J, David B. Endophthalmitis after Intravitreal Injection. Retina. 2011;31(8):1525-1533.
9. Brian L, VanderBeek BL, Bonaffini SG, Liyuan M. Association of Compounded Bevacizumab with Postinjection Endophthalmitis. JAMA Ophthalmol. 2015;133(10):1159-1164.
10. Nadim R, Ehsan R, Philip S, Chirag PS, Wolfe JD, Chen E, DeCross C, Garg SJ. Post-injection Endophthalmitis Rates and Characteristics Following Intravitreal Bevacizumab, Ranibizumab, and Aflibercept. Am J Ophthalmol. 2016;165:88-93.
11. Englander M, Chen TC, Eleftherios PI, Miller JW, Kim IK. Intravitreal injections at the Massachusetts Eye and Ear Infirmary: analysis of treatment indications and postinjection endophthalmitis rates. Br J Ophthalmol. 2013;97(4):460-465.
12. Bhatt SS, Stepien KE, Komal JB. Prophylactic Antibiotic Use after Intravitreal Injection: Effect on Endophthalmitis Rate. Retina. 2011;31(10):2032-2036.
13. Storey P, Dollin M, Rayess N, Pitcher J, Reddy S, Vander J, Hsu J, Garg S. The effect of prophylactic topical antibiotics on bacterial resistance patterns in endophthalmitis following intravitreal injection. Graefe's Archive for Clinical and Experimental Ophthalmology. 2016;254:235-242.
14. Garg SJ, Dollin M, Hsu J, Vander JF, Storey P. Effect of a Strict 'No-Talking' Policy During Intravitreal Injection on Post-Injection Endophthalmitis. Ophthalmic Surgery, Lasers and Imaging Retina. 2015;46(10):1028-1034.

DOI: *10.46998/IJCMCR.2020.03.000069*