

The Slow Rhythm of Midodrine: A Peculiar Case of Profound Bradycardia

Larissa Check, D.O., M.Sc.^{1,3}, Louis Tsihchlis D.O.², Mohamed Faris M.D.¹

¹Department of Internal Medicine. Grand Strand Medical Center, Myrtle Beach, SC, USA

²Department of Anesthesiology. Grand Strand Medical Center, Myrtle Beach, SC, USA

*Corresponding author: Larissa Check, Department of Internal Medicine, Grand Strand Medical Center, Myrtle Beach, SC, USA, Email: Larissa.check@hcahealthcare.com

Received: April 30, 2022

Published: May 30, 2022

Abstract

Shock is a state of decreased organ perfusion that is life-threatening and requires emergent medical intervention [1]. As such, patients who present with shock are often managed in the critical care unit with intravenous fluid boluses and vasoactive agents. The ultimate goal is to prevent multi-system organ failure and to achieve a mean arterial pressure >65mmHg. Oral Midodrine has been hailed as an adjunctive therapy in critical care patients with refractory hypotension [2, 3, 4, 5]. However, Midodrine is only FDA approved, and remains the sole treatment for symptomatic orthostatic hypotension [6]. The mechanism of action is through alpha-1 adrenergic activation leading to an increase in vascular tone [2, 3, 4, 5]. Midodrine does not stimulate cardiac beta-adrenergic receptors, however its use can result in profound bradycardia [6]. We present a case of a 53-year-old patient in hypovolemic shock, refractory to fluid resuscitation who developed profound bradycardia after the initiation of Midodrine. This case highlights an overlooked and potentially dangerous side effect of a commonly used, off-label indication for this medication.

Keywords: Hypovolemic Shock; Critical Care Medicine; Refractory Hypotension; Midodrine-Induced bradycardia; Reflex bradycardia; Case Report

Introduction

Midodrine is a short-acting vasopressor approved by the FDA in 1996 for orthostatic hypotension. It belongs to the drug class alpha-1-receptor agonist which increases vascular tone and raises blood pressure. Midodrine is historically used to treat patients with symptomatic low blood pressure when a patient moves from sitting to standing, known as orthostatic hypotension. Midodrine is also proved to be a safe way to prevent a drop in blood pressure inpatients during dialysis sessions because it maintains vascular tone. More recently, Midodrine has been used in the ICU setting to maintain patients' mean arterial blood pressure when they are being weaned off other vasopressors. It has also been used in adjunct with other vasopressors, or alone. Midodrine comes in 2.5mg, 5mg and 10mg tablets, which can be taken orally three times a day. It is rapidly absorbed, reaching peak serum concentrations around one hour and having a half like of 3-4 hours. It is metabolized in the liver and secreted in the urine. Midodrine has a mild side effect profile with common side effects including paresthesias, dysuria, hypertension and rash. More serious reactions include bradycardia, and visual field deficits.

Case Presentation

The patient is a 53-year-old female with a history of Crohn's disease (diagnosed at 18 y/o) who presented with nausea, non-bilious emesis and concerns for high output ostomy. The patient had a total colectomy and ileostomy (at 21 years old) which was revised at 23 years old due to a small bowel flare-up

requiring the small intestines to be moved to the left side (no J-pouch or colectomy stump). On presentation she reported left lower quadrant abdominal pain that was 8 to 10/10 in severity, intermittent, sharp in quality and non-radiating. She also reported 300-500 mL in her ileostomy bag every hour, which has increased from her usual 250 mL. She also reported a reduced appetite over the past 4 days with a 7-pound weight loss prior to arrival. The patient denied recent GI illness, smoking, alcohol, or recreational drug abuse. She also denies any extra-intestinal manifestations such as a rash, blurry vision, muscle/joint pain, chest pain, palpitations or back pain.

Initial vitals were stable with pulse ranging 76 to 104 beats per minute and blood pressure from 107/56 to 142/88 mmHg. Complete blood count was unremarkable. Comprehensive metabolic panel was remarkable for acute renal injury, hypokalemia and hypomagnesemia. On exam, the patient was non-toxic in appearance with regular heart sounds and clear lungs on auscultation. Her abdomen was soft, minimally tender to palpation and a left ileostomy bag was noted in place with approximately 200cc of liquid brown stool. Blood cultures and stool cultures were collected. Management initially focused on acute gastroenteritis with initiation of intravenous fluids due to concerns for hypovolemia. Over the course of 24 hours, her blood pressure dropped in spite of aggressive fluid resuscitation. Midodrine was initiated at 5mg three times daily and the patient was transferred to the ICU.

Gastroenterology was consulted for further management and evaluation of the patient's Crohn's Disease, high output os-

tomy, and intractable nausea and vomiting. She had a bedside endoscopy which revealed normal esophagus and stomach. Given the fact that the patient had been in clinical remission of Crohn's Disease for many years, there was little evidence to support the fact that her presentation represented an active Crohn's flare over probable infectious etiology. Workup including Giardia amoeba antigen, Hepatitis panel, stool studies and PCR for bacterial causes of gastroenteritis were negative. Antimotility agents were initiated to decrease output. The patient was advised to avoid all dairy, artificial sweetener and greasy meals. Furthermore, steroids were discontinued as there was no evidence for active disease of the small bowel on a follow up CT heterography.

The intriguing part about the case was reflected in the patient's response to Midodrine. As noted above, the patient was in hypovolemic shock with initial blood pressure readings as low as 80/50 mmHg and heart rates between 90 to 110 beats per minute. After the initiation of Midodrine, the patient's blood pressure improved to 110/60 mmHg, however her pulse rate remained within the range of 39 to 60 beats per minute on telemetry (Figure 1). The patient was not on any atrioventricular nodal blocking agents and was asymptomatic.

Midodrine was initiated at 18:51 when the mean arterial pressure (MAP) was 60 and the heart rate was 100 (Figure 2, first

blue arrow). Approximately 20 hours later at 15:30, the MAP was in the mid-70s and the heart rate was 55 (Figure 2, second blue arrow). The graph represents the documented vitals by nursing staff. However, it must be noted that on telemetry reading, the heart rate did drop below 40 within the next 48 hours. Midodrine was discontinued on the fourth day at 10:00 (Figure 2, third blue arrow), after which it was noted that the pulse rate recovered appropriately over 24 hours.

Discussion

Shock is a state of decreased organ perfusion that is life-threatening and requires emergent medical intervention. As such, patients who present with shock are hemodynamically unstable and require high acuity care. In critical care and emergency medicine, hemodynamic instability is managed with 30cc per kg boluses of intravenous fluid and vasoactive agents. The ultimate goal of intravenous fluid resuscitation and vasopressors is to prevent multi-system organ failure and to achieve a mean arterial pressure that is greater than 65 mmHg. Refractory hypotension results when patients remain hypotensive despite receiving the appropriate resuscitative fluids and vasopressors. Oral Midodrine has been hailed as an adjunctive therapy in critical care patients with refractory hypotension. It has also been beneficial in patients who become hypotensive during hemodialysis. Nonetheless, Midodrine is only FDA approved

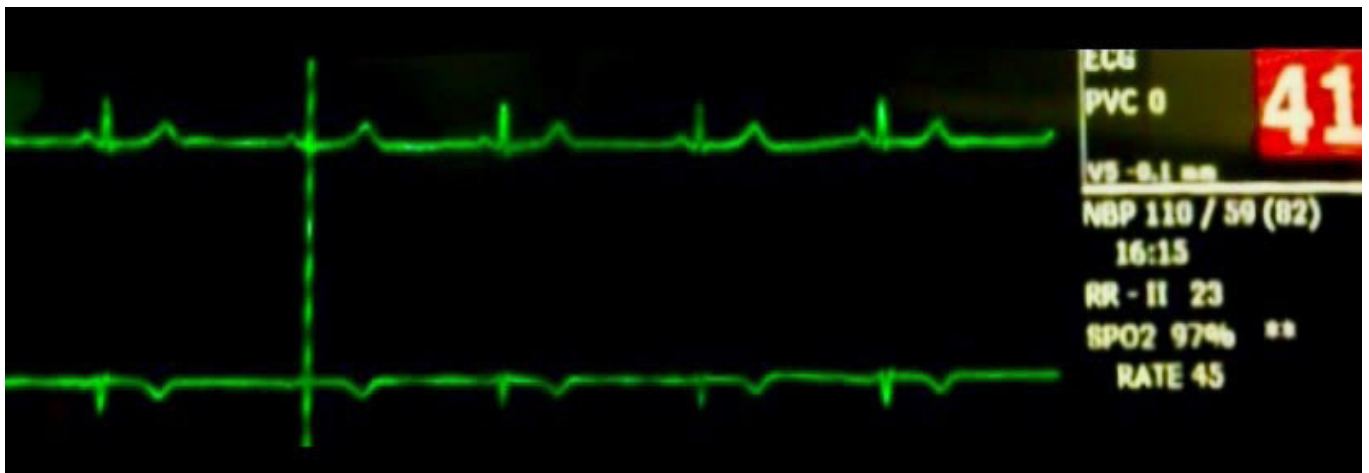

Figure 1: Telemetry strip showing profound sinus bradycardia and normal P-R interval. There was no evidence of pauses, heart block or P-Qrs dissociation.

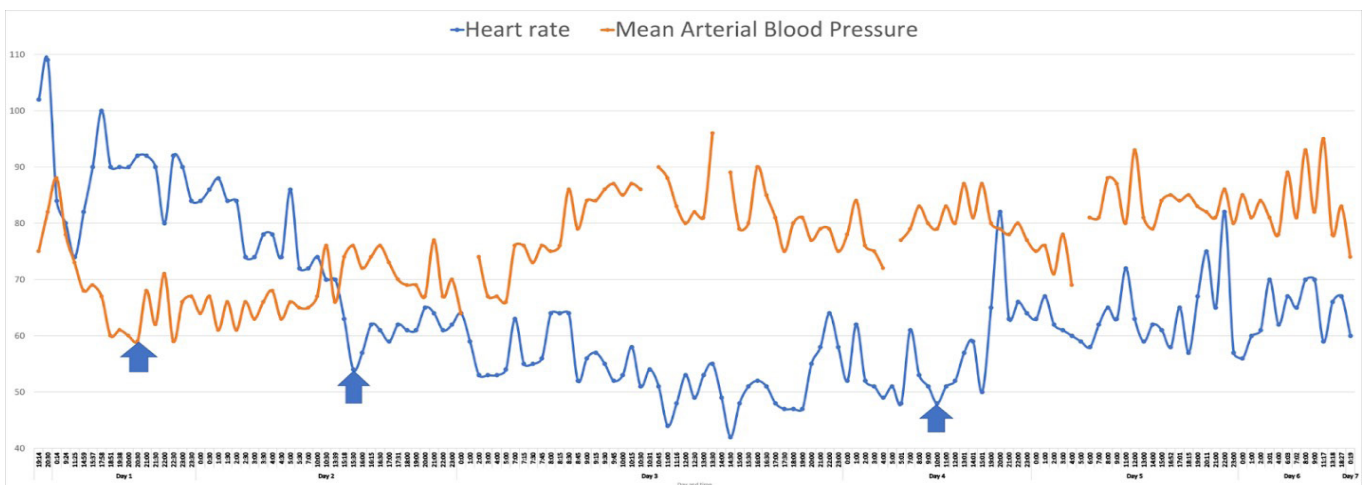


Figure 2: A graphic representation of mean arterial blood pressure (blue curve) versus heart rate (orange curve) in the setting of Midodrine administration. The x-axis (day and times) represents the real time recordings by nursing staff. The first arrow represents time when the patient received the first dose of Midodrine and the corresponding MAP and heart rate. The second arrow represents the time when the team noted an initial drop of heart rate with improvement in the MAP. And the last arrow represents the MAP and heart rate when Midodrine was discontinued.

for the treatment of symptomatic orthostatic hypotension. The mechanism of action is through alpha-1 adrenergic activation leading to an increase in vascular tone and hypertension. Midodrine does not stimulate cardiac beta-adrenergic receptors, however its use can result in profound bradycardia.

Review of the current literature suggests that Midodrine causes reflex bradycardia primarily through activation of the baroreceptors. These receptors sense when there is an unusual increase in blood pressure. Physiologically, Blood Pressure (BP) is determined by Stroke Volume (SV), Heart Rate (HR) and Total Peripheral Resistance (TPR) as such $BP = SV \times HR \times TPR$. In an unregulated system, increase in TPR through vasoconstriction should directly increase blood pressure. However, when the carotid sinus senses this increase in blood pressure, signals are to the central homeostatic center—the medulla oblongata, which then activates a vagal response. Acetylcholine is released as a result and binds to the M2 muscarinic receptors. These receptors are located on cardiac muscle and act primarily by reducing conduction velocity through the atrioventricular node leading to bradycardia. The electrocardiogram will show signs of delayed depolarization but normal P-R intervals and consistent P-QRS association.

In Critical Care and Progressive Care patients, our goals in correcting hypotension include providing volume support and/or pressure support. In refractory hypotension cases where volume resuscitation does not improve hypotension, we must focus on providing pressure support. Midodrine is a typical first-line agent in providing pressure support through its effects as an agonist on alpha-1 adrenergic receptors. Of note, midodrine's mechanism of action can be compared to that of phenylephrine, epinephrine and also norepinephrine which predominantly acts as an agonist on alpha-1 adrenergic receptors. Although phenylephrine, epinephrine and norepinephrine are common vasopressor agents used in the setting of Critical Care and Anesthesia, midodrine is not. Due to midodrine's nature as an oral medication that is commonly used outside of Critical Care and Anesthesia, the effect of reflex bradycardia often seen in vasopressor agents used in Critical Care and Anesthesia can be overlooked. The significance of this is that reflex bradycardia from midodrine administration can worsen hypotension and increase the requirement for further vasopressor agent support. This ultimately prolongs the course of treatment needed in the Critical Care setting.

When discussing our current case, the way in which prolonged Critical Care treatment was mitigated was through the discontinuation of midodrine administration after noting our patient's bradycardic response. Since the half-life of midodrine is 3-4 hours while the half-life of vasopressor agents used in Critical Care/Anesthesia range from 2-5 minutes, it was important to hemodynamically monitor our patient for the duration of midodrine's clearance [7]. In our patient's case, the effect of reflex bradycardia resolved after 24 hours of midodrine discontinuation. Additionally, it is essential to note that our patient did not have an underlying renal pathology which would have prolonged the clearance of midodrine [7,8].

Conclusion

Overall, when administering midodrine it is essential to understand the underlying mechanism of action and side effects which can be compared to vasopressors used in the setting of Critical Care and Anesthesia. Similar to phenylephrine, epinephrine and norepinephrine, midodrine acts as an agonist at alpha-1 adrenergic receptors in effect improving hypotension

through vasoconstriction. Importantly, this vasoconstriction can lead to reflex bradycardia as seen in this case report involving midodrine. While the resolution of reflex bradycardia can be seen shortly after discontinuation of vasopressor agents used in Critical Care/Anesthesia, the resolution of reflex bradycardia after discontinuation of midodrine is more prolonged. Due to this, we must note the importance of hemodynamic and symptomatic monitoring following the discontinuation of midodrine. In this case, we saw a resolution of reflex bradycardia 24 hours after the discontinuation of midodrine.

Furthermore, given the fact that Midodrine is frequently used off label in hypotensive patients, this case serves as a cautionary finding to not only avert excessive workup for bradycardia, but also alert clinicians to this underreported side effect. Midodrine should be stopped especially if the patient experiences symptomatic bradycardia or shows evidence of reduced cardiac output. As such, the case importantly highlights an overlooked and potentially dangerous side effect of a commonly used, off-label indication for Midodrine.

Disclosures: Special thanks to Vivian Louviere B.Sc for valuable feedback on this paper

Author Contributions: All authors contributed to this manuscript. L. Check is the article guarantor.

Financial Disclosure: None to report.

HCA Healthcare disclaimer: "This research was supported (in whole or in part) by HCA Healthcare and/or an HCA Healthcare affiliated entity. The views expressed in this publication represent those of the author(s) and do not necessarily represent the official views of HCA Healthcare or any of its affiliated entities."

Informed written consent was obtained for this case report.

References

- Lier H, Bernhard M, Hossfeld B. Hypovolämisch-hämorrhagischer Schock [Hypovolemic and hemorrhagic shock]. *Anaesthesist*, 2018; 67(3): 225-244. German. doi: 10.1007/s00101-018-0411-z. PMID: 29404656.
- Anstey MH, Wibrow B, Thevathasan T, Roberts B, Chhangani K, Ng PY, et al. Midodrine as adjunctive support for treatment of refractory hypotension in the intensive care unit: a multicenter, randomized, placebo-controlled trial (the MIDAS trial). *BMC Anesthesiol*, 2017; 17(1): 47. doi: 10.1186/s12871-017-0339-x. PMID: 28327122; PMCID: PMC5361788.
- Levine AR, Meyer MJ, Bittner EA, Berg S, Kalman R, Stanislaus AB, et al. Oral midodrine treatment accelerates the liberation of intensive care unit patients from intravenous vasopressor infusions. *J Crit Care*. 2013; 28(5): 756-762. doi: 10.1016/j.jcrc.2013.05.021. Epub 2013 Jul 8. PMID: 23845791.
- Poveromo LB, Michalets EL, Sutherland SE. Midodrine for the weaning of vasopressor infusions. *J Clin Pharm Ther*, 2016; 41(3): 260-265. doi: 10.1111/jcpt.12375. Epub 2016 Mar 4. PMID: 26945564.
- Al-Abdoun A, Haddadin S, Matta A, Jabri A, Barbarawi M, Abusnina W, et al. Impact of Adjuvant Use of Midodrine to Intravenous Vasopressors: A Systematic Review and Meta-Analysis. *Crit Care Res Pract*, 2021; 2021: 5588483. doi: 10.1155/2021/5588483. PMID: 34055408; PMCID: PMC8147551.
- Drugs@FDA: FDA-Approved Drugs. Action Date Submission Supplement Categories or Approval Type
- Macielak SA, Vollmer NJ, Haddad NA, Nabzyk CGS, Nei SD. Hemodynamic Effects of an Increased Midodrine Dosing Frequency. *Crit Care Explor*, 2021; 3(4): e0405.
- Blowey DL, Williamson Balfé J, Gupta I, Gajaria MM, Koren G. Midodrine efficacy and pharmacokinetics in a patient with recurrent intradialytic hypotension. *American Journal of Kidney Diseases*, 1996; 28(1): 132-136. doi:10.1016/s0272-6386(96)90142-0