

Vulval Leiomyoma

Nagat Bettamer^{1*}, Ream Langhe^{1*}, Zahia Elghazal, Farag Ben Ali¹, Lamia Alkikhia²

¹Department of Obstetrics and gynaecology, University of Benghazi, Benghazi, Libya

²Department of Histopathology, University of Benghazi, Benghazi, Libya

Received: October 20, 2020

Published: December 09, 2020

Abstract

The authors present a rare case of vulval swelling in a 2-year period in a 35-year old woman. The swelling was associated with mild vulval discomfort but no other symptoms. The tumour was removed surgically with no complications. Histopathology of the swelling confirmed vulval leiomyoma. Postoperative recovery was unremarkable and the woman was discharged on postoperative day 2.

Keywords: Leiomyoma; Swelling; Vulva

Case Presentation

A 35 year old patient presented to our department with a history of painless left vulval swelling of over a duration of two years. The swelling was slowly growing and associated with mild discomfort but no other symptoms. The woman had three previous uncomplicated vaginal deliveries and her last delivery was 3 years ago. The woman was non-smoker and of a normal BMI. Her medical and surgical histories were unremarkable. There was no family history of any malignancies.

On examination, the patient was well, and her vitals were stable. Examination of her breasts and abdomen was unremarkable.

Local examination:

Showed enlarged left side vulval swelling 12×10 cm, firm, fairly mobile with no tenderness and no signs of inflammation (Figure 1). The uterus was of normal size and there was no adnexal mass.

Abdominal, transvaginal and transperineal scan revealed a cystic swelling in the left vulva with degenerative changes. No other pathology was detected in the scan.

The woman was counselled and consented for surgical excision under general anesthesia. At surgery, a vertical incision was performed on the inner side of the left labium majus. The tumour was inoculated and excised. Homeostasis was secured and the tissues sent for histopathology (Figures 2 a&b).

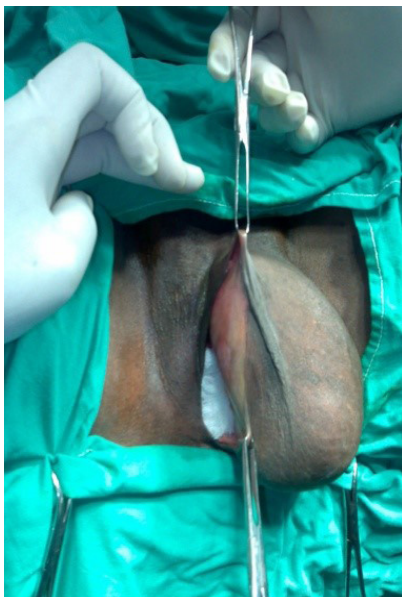


Figure 1: Left vulval swelling

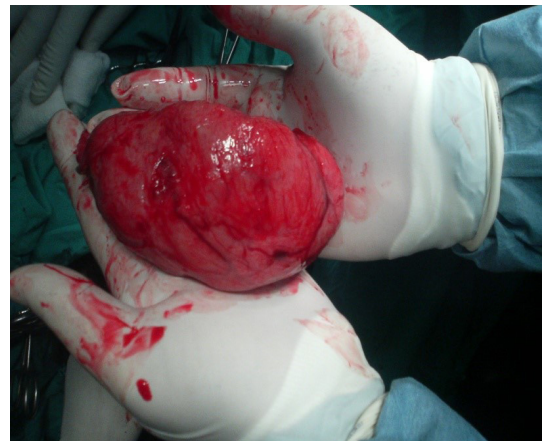


Figure 2a: shows a swelling removed from left vulva.

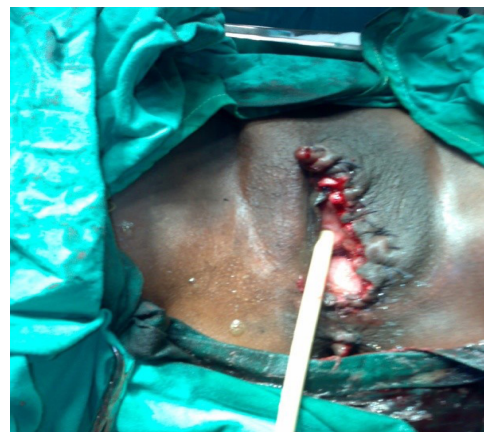

Figure 2b: illustrates vulva appearance after removal of swelling.

Histopathology Report

Gross examination revealed a well circumscribed non encapsulated soft tissue firm mass 12×11 ×13cm size grey whorled with yellow spots.

Microscopy: the section revealed a benign neoplasm composed of interlacing bundles of spindled cells with abundant eosinophilic cytoplasm and delicate fibrovascular stroma with areas of many blood vessels, no malignancy (Figure 3). The diagnosis confirmed vulval leiomyoma.

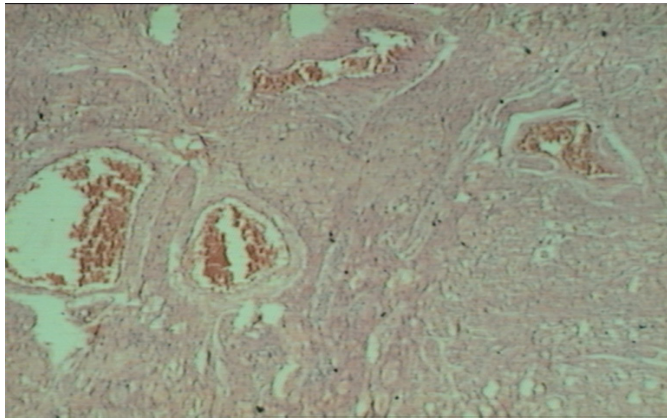


Figure 3: Illustrates smooth muscle fibres with blood vessels.

Discussion

Vulvar leiomyoma is a rare type of benign tumours of smooth muscle cells. So far, about 160 cases of vulval leiomyoma have been reported in English literature [1-4].

Vulvar leiomyomas occur during the reproductive years and most patients present with a painless nodule or swelling in the labia. This benign tumour usually remains small for long period of time and grows slowly in the early period. As the swelling increases in size patients started to experience symptoms such as pain, itching and erythema [5,6]. The patient in index was asymptomatic for 2 years and she did not seek any medical advice until she started to experience discomfort.

Differential diagnosis of vulval leiomyoma include, Bartholin cyst, Bartholin abscess, fibromas, lymphangiomas, soft-tissue sarcomas, and neurogenic tumours [5]. Differentiation between benign and malignant vulval lesions can be challenging. This is due to rarity of the lesions and non-specific clinical presentation [7]. On examination, vulval leiomyoma are usually non-tender, mobile with firm consistency [8-11].

Ultrasound is the most reliable imaging tool in establishing the diagnosis of uterine and extrauterine leiomyoma [5,12]. Magnetic resonance imaging (MRI) is useful in differentiating benign and malignant lesions in difficult cases [4,5]. A character-

istic feature of malignant lesions on MRI is low signal intensity on T2-weighted images [1].

Surgical excision of the tumour along with some of the surrounding tissues is the treatment of choice of vulval leiomyoma [1,3,4]. Histologically, leiomyomas of the vulva are generally similar to their more commonly occurring counterparts in the uterine body. Follow up after surgery is recommended because of risk of recurrence.

Conclusion

Vulval leiomyoma is a rare type of benign tumour in the vulva. This condition is often misdiagnosed as Bartholin cyst. Transperineal ultrasound helps in establishing the diagnosis. Surgical excision is the best current treatment available and histopathology confirmed the diagnosis. Postoperative follow up is highly recommended for these patients.

References

1. Fasih N, Prasad Shanbhogue AK, Macdonald DB, Fraser-Hill MA, Papadatos D, Kielar AZ, Doherty GP, Walsh C, McInnes M, Atri M. Leiomyomas beyond the uterus: unusual locations, rare manifestations. *Radiographics*. 2008; 28(7):1931-1948.
2. Reyad MM, Gazvani MR, Khine MM. A rare case of primary leiomyoma of the vulva. *Journal of obstetrics and gynaecology*. 2006; 26(1):73-74.
3. Zhao T, Liu X, Lu Y. Myxoid epithelial leiomyoma of the vulva: a case report and literature review. *Case reports in obstetrics and gynecology*. 2015.
4. Kurdi S, Arafat AS, Almegbel M, Aladham M. Leiomyoma of the Vulva: a diagnostic challenge case report. *Case reports in obstetrics and gynecology*. 2016.
5. Pandey D, Shetty J, Saxena A, Srilatha PS. Leiomyoma in vulva: a diagnostic dilemma. *Case reports in obstetrics and gynecology*. 2014.
6. Nielsen GP, Rosenberg AE, Koerner FC, Young RH, Scully RE. Smooth-muscle tumors of the vulva: a clinicopathological study of 25 cases and review of the literature. *The American journal of surgical pathology*. 1996; 20(7):779-793.
7. Safaa A, Chourouk E, Najia Z, Amina L, Abdelaziz B. Vulvar leiomyoma: a case report. *The Pan African Medical Journal*. 2019; 32.
8. Sun C, Zou J, Wang Q, Wang Q, Han L, Batchu N, Ulain Q, Du J, Lv S, Song Q, Li Q. Review of the pathophysiology, diagnosis, and therapy of vulvar leiomyoma, a rare gynecological tumor. *Journal of International Medical Research*. 2018; 46(2):663-674.
9. ROY KK, Mittal S, Kriplani A. A rare case of vulval and perineal leiomyoma. *Acta obstetrica et gynecologica Scandinavica*. 1998; 77(3):356-357.
10. Kransdorf MJ, Meis-Kindblom JM. Dermatofibrosarcoma protuberans: radiologic appearance. *AJR. American journal of roentgenology*. 1994; 163(2):391-394.
11. Ngo Q, Haertsch P. Vulvar leiomyoma in association with gastrointestinal leiomyoma. *The Australian & New Zealand journal of obstetrics & gynaecology*. 2011; 51(5):468.
12. Tavares KA, Moscovitz T, Tcherniakovsky M, Pompei LD, Fernandes CE. Differential diagnosis between Bartholin cyst and vulvar leiomyoma: case report. *Revista Brasileira de Ginecologia e Obstetria*. 2017; 39(8):433-435.